



Therapy concept for Surgical Uprighting of the Impacted Second Mandibular Molar

Authors

Dr. Benjamin Shlomi¹, Prof. Dr. Nezar Watted², Dr. Muhamad Abu-Hussein³

¹The Sourasky Medical Centerl, University of Tel Aviv, Tel -Aviv/Israel

²Center for Dentistry research and Aesthetics, Jatt/Israel

³Department of Pediatric Dentistry and Orthodontics, University of Athens, Greece

Corresponding Author

Dr. Benjamin Shlomi

The Sourskz Medical Center, University of Tel- Aviv

Tel Aviv, Israel

Email; abuhusseinmuhamad@gmail.com

Abstract

Impaction of permanent teeth is a relatively common occurrence and can involve any tooth in the dental arch. Impacted mandibular second molars are less frequently encountered, but when they occur they may present a challenging treatment procedure for the orthodontist and oral surgeon, they may require auxiliary appliances. Generally the definitive treatment of these Impactions is carried out at the age of 11-to 14-years old range. These impaction ma by associated with a third molar impaction.

The possibilities of second molar impaction treatments is surgical removal of second molar and allowing third molar to erupt, transplantation of third molar to the second molar space, surgical repositioning of second molar with or without third molar extraction. The most promising results was seen in cases of repositioned second molar. The timing of treatment and the biomechanics involved determine the success

Purpose of this article to describe the surgical repositioning of second molar with third molar extraction

Key words: *impaction, second molar, surgical uprighting, surgical exposure*

Introduction

Impaction of a permanent tooth is a relatively common clinical occurrence that may involve any tooth in the human dentition. Impacted mandibular second molars are a rather uncommon problem with an incidence of 3 in 1,000 and often pose a challenge for orthodontists and oral surgeons [2].

A tooth is impacted when it fails to erupt due to an obstacle such as the presence of a supernumerary tooth or an odontoma, lack of adequate space in the arch, an abnormal eruption path, or with no apparent etiology [2,3]..

Unilateral impaction is a more common problem and more frequently affects the right side of the mandible of male patients.

Surgical approaches for impacted second molars include surgical extraction to allow eruption of the third molars, surgical uprighting of the impacted second molars, surgical uncovering with orthodontically assisted eruption and transplantation of the third molars to the second molar sockets. However, orthodontic uprighting might be a better alternative with a lower risk to the teeth. With the recent development of miniscrews, its clinical application has become various and predictable.^[5] Placing titanium miniscrews in the retromolar area for molar uprighting was recommended by Giancotti et al.^[13] (Fig. 1).

The best time to treat impacted mandibular second molars is between 11 and 14 years of age, when development of the second permanent molar roots is still incomplete. The treatment options depend on the degree of tooth inclination as well as the required tooth Movement^[6].

It is essential to diagnose and treat eruption disturbances as soon as possible because treatment at a later stage is usually more complicated due to the tendency of malocclusion to increase with time and decrease the ability of remaining dentition to adjust^[4]. Oral hygiene at home becomes more straightforward and effective, thanks to the elimination of the pseudo-pocket. The incidence of caries is much higher in impacted teeth, and there is often radiographic evidence of severe damage to the crown or root of the first permanent molar^[7].

Treatment Options

1. Orthodontic treatment only, using levers and coiled springs to distalize the inclined tooth.
2. Combined surgical and orthodontic treatment: surgical exposure from soft and hard tissue, followed by banding or bracketing of the molar, performed intraoperatively or soon after (Fig. 1).
3. Surgical therapy: either extraction of the impacted tooth or surgical uprighting (Fig. 2a-J)

Surgical Options

There are more than an option for treating an impacted second molar:

1. Extraction of an impacted mandibular second molar which appears to have no chance of uprighting itself may allow the third molar to erupt into the second molar position. This requires precise manipulation by the oral surgeon, who must carefully consider the unpredictability of these eruption patterns.
2. Surgical methods vary from simply uncovering the tooth to third molar extraction and surgical second molar repositioning, with or without bone grafts in the medullar space (Fig.2a-j).
3. Surgical uprighting and repositioning of the mandibular second molar, with or without extraction of the third molar, is a possible option.

When a molar tooth is severely impacted, surgical uprighting may provide a quick and easy solution, particularly when orthodontic treatment is contraindicated. When the decision has been made to perform surgical uprighting and repositioning second molars, Tinerfe and Blakey^[8]. recommend that certain criteria be considered.

These include ascertainment of root length/form, available space within the dental arch, arc of rotation, occlusion, periodontal status and jaw development. The optimal root length should be one-third to half of the eventual length of the fully formed root, to enhance revascularization after tipping and bodily movement. As adequate space must be available in the arch, third molars may need to be prophylactically removed.

Ideally, the tooth to be uprighted should not be buccally or lingually inclined, since the buccal and lingual cortical plates are needed for primary stabilization once the second molar is surgically uprighted.

Once the molar has been uprighted, any occlusion should be carefully checked for interferences which may lead to occlusal trauma. The uprighted tooth also should be positioned in a manner which allows healthy soft tissue attachment and ease of access for appropriate hygiene. Careful handling and positioning of the keratinized gingiva during the procedure are critical for the long-term periodontal health of uprighted molars.

It is also important that vertical jaw growth should be nearly complete, to achieve ideal occlusion and prevent tooth submersion during growth. If these criteria are met, surgical second molar uprighting has been shown to be a predictable procedure and

a viable option when other types of treatment are not possible^[9].

A surgical exposure and uprighting of second molar with the extraction of the third molar tooth

Before performing the surgical intervention, we should examine the interocclusal clearance of the posterior dentition, in order to verify that sufficient vertical space exists between the impacted second molar tooth, in the mandible and the opposing maxillary molar tooth. A removal or fixed, bite opening appliance for the Decoupling of the occlusion, has to be prepared prior to the procedure surgical (uprighting), in order to prevent any intolerable malocclusion.

The second prerequisite, for the procedure to be performed, is the presence of a third molar tooth bud, whose removal will create the necessary space required for the second molar uprighting.

The surgical procedure, itself, can be carried out under local anesthesia with or without conscious sedation.

A muco-gingival incision is made and a muco – periosteal flap extending from the first molar to the retromolar area from the buccal side, and a limited lingual flap, at the retromolar area, is reflected .as to expose the bone surrounding the impacted second molar and also the unerupted third molar tooth bud (Fig-2a-d).

Bone is carefully removed, as required, for the third molar bud extraction. Bone is also removed in order to expose the height of the crown of the impacted second molar tooth. Then a sharp, straight elevator is placed at a purchase point, at the mesio-buccal aspect of the impacted second

molar tooth and using a controlled force ,the second molar is rotated distally and elevated past the contact point with the first molar ,present in the dental arch (Fig. 2e, f) .

The occlusion is checked for any major premature contacts with the opposing maxillary dentition and those are slightly ground if necessary.

In the great majority of cases, the uprighted tooth is self stabilized, by being wedged between the buccal and lingual bone plates and leaning against the contact point with the adjacent, first molar tooth. Only few cases has to be stabilized Intra or post operatively with the application of wire and composite fixation or orthodontic bracketing.

Soft tissue closure is done in an ordinary fashion, using resorbable or unresorbable sutures. In selected cases, apically repositioned flaps, has to be incorporated, in order to better expose the uprighted tooth crown. This procedure is often unnecessary because the crown will erupt from the surrounding soft tissue envelope past a short period of time. If orthodontic alignment is still necessary, postoperatively it can be started at six weeks after he surgical procedure (Fig. 2g, f).

An immediate post operative x-ray is taken (Fig. 2i) and a panoramic post operative is obtained at six month and eighteen month post operatively .By that time, bony healing is completed (Fig. 2j) .

Discussion

The article discusses the methods of treating an impacted second molar tooth with Surgical uprighting and repositioning, an issue relatively little discussed in the literature due to the low prevalence of this kind of malocclusion.

The method described is minimally invasive, as the surgery needed to expose the impacted tooth, together with extraction of the third molar, which is necessary in these cases. It also seems that the creation of a cortico-medullar void distal to the second molar, after third molar extraction or appositely surgically performed, is important for the surgical uprghing ^[10].

Different treatment options are discussed in the literature. Generally, surgical repositioning and transplantation brings a higher risk of complications, such as pulp necrosis, ankylosis, or root resorption, and therefore should be applied only when orthodontic treatment is contraindicated. If surgical methods are a preferred treatment, it is important to know that surgical repositioning gives a better long-term prognosis than transplantation because the tooth is not removed from the socket.

A less risky alternative is orthodontically assisted eruption with or without surgical uncovering; this depends on the degree of impaction. The choice of appliance should be based on proper evaluation of impacted molars and the developing third molar position. Other factors, such as the degree of impaction and desired type of movement, should also be considered when choosing an appliance.

Prior to orthodontic therapy, the need for third molar extraction should be evaluated ^[11]. Frequently, the third molar position may impede the distal movement of the impacted molar, indicating the need for extraction. However, from a biomechanical perspective, sometimes it is better to leave the third molar bud to facilitate the second molar rotation ^[12].

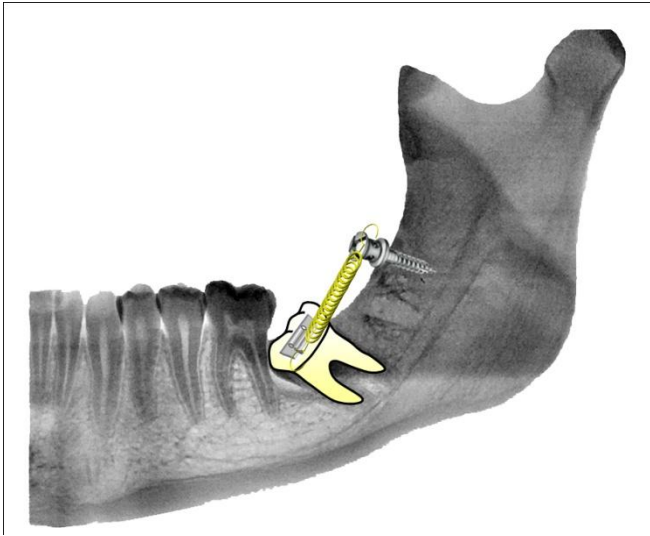


Fig.1: Combined surgical and Orthodontic treatment. Example of screw positioning in retromolar area for the application of force during the uprighting. Lateral view.

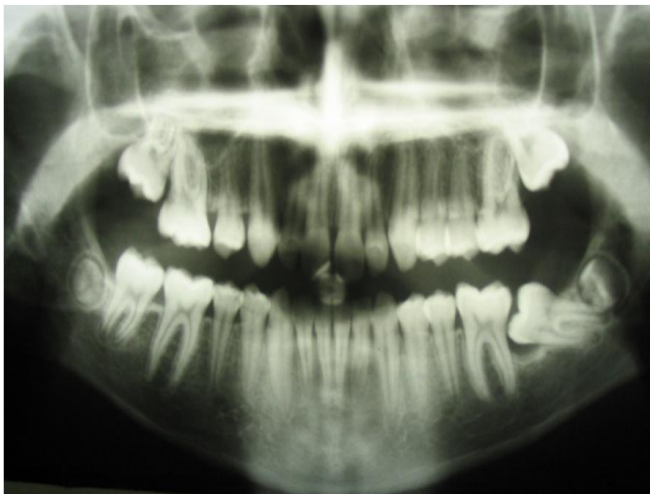

Fig.2a: Orthopantomogram : Eruption disorder of the left second lower molar with complete gingival inclusion

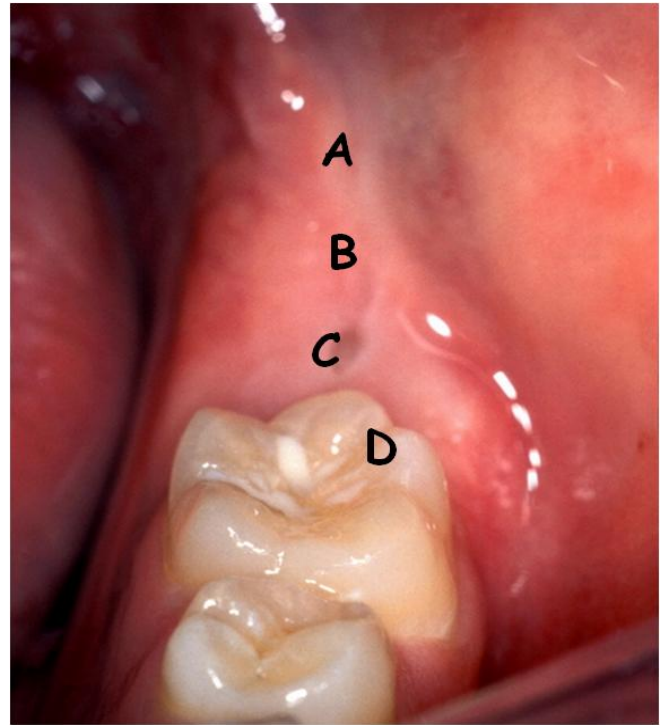


Fig.2b: clinical situation of the same patient before exposure. (A) Retromolar area. (B) area of the displaced and impacted Third molar. (C) Impacted second molar (D). First molar.

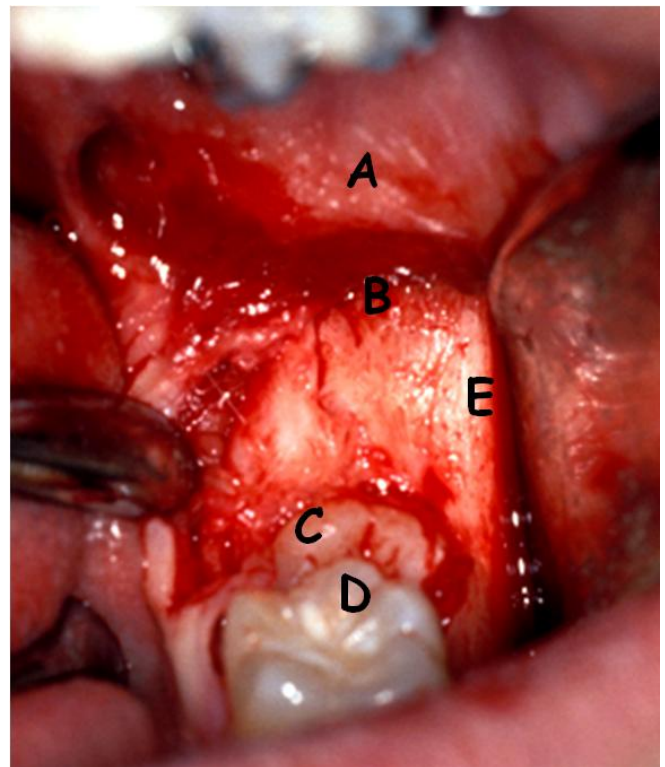


Fig.2c: Surgical exposure: (A) Retromolar area. (B) area of the displaced and impacted Third molar. (C) Impacted second molar (D). First molar. (E) Oblique external line.

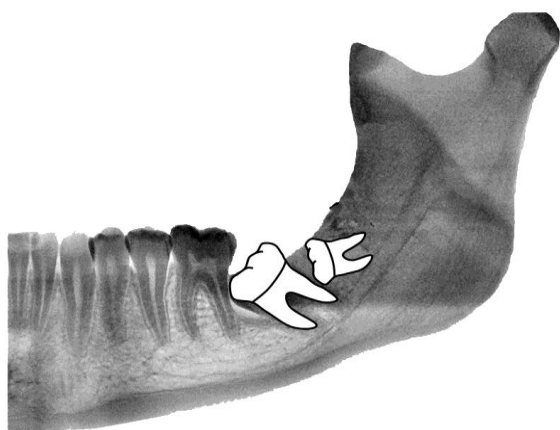


Fig.2d: schematic view of the clinical situation

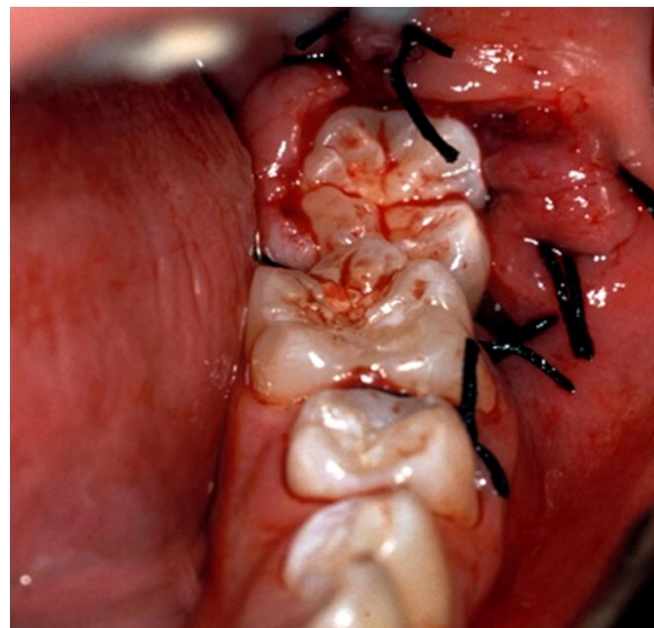


Fig.2g: Surgical exposure and Uprighting the second molar

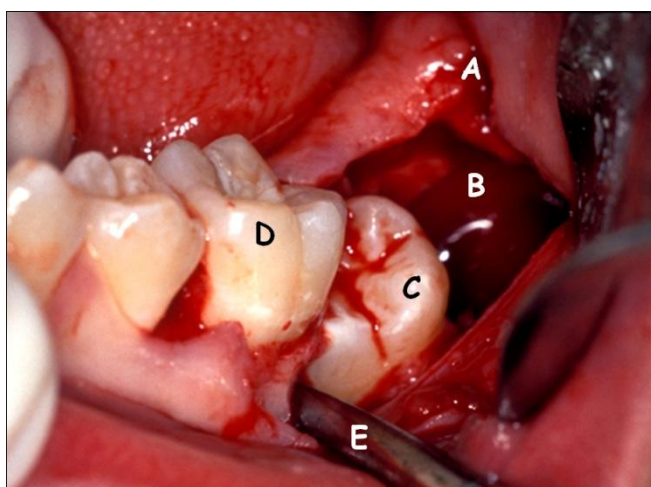


Fig.2e: Surgical exposure and before the Uprighting:. (A) Retromolar area. (B) Third molar extraction socket (C) Impacted second molar (D). First molar. (E) Oblique external line

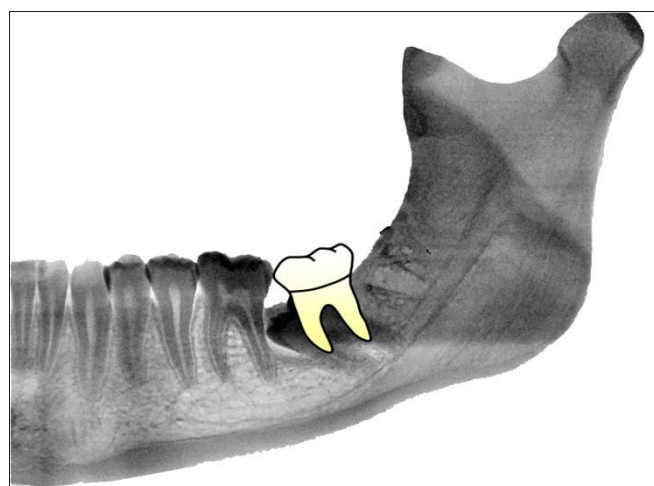


Fig.2h: schematic view of the clinical situation after Extraction the third molar and Uprighting

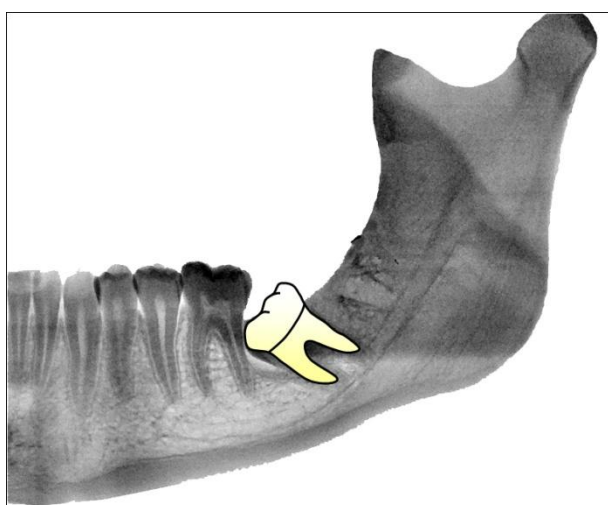


Fig.2f: schematic view of the clinical situation after Extraction the third molar

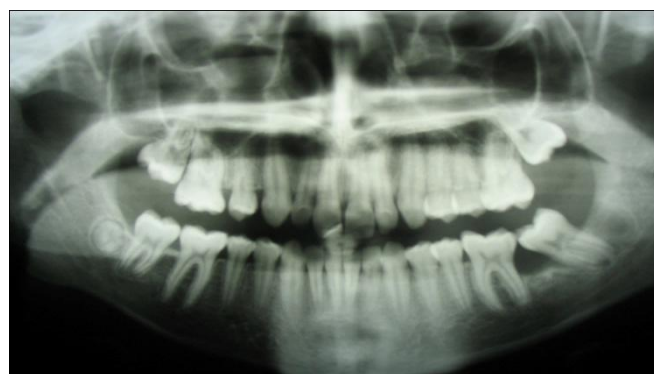

Fig.2i: Orthopantomogram six month post operatively

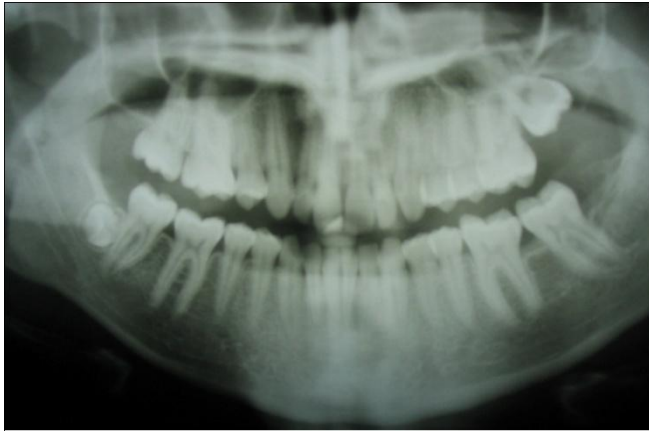


Fig.2j: Orthopantomogram eighteen month post operatively

Conclusions

Second molar impaction is a very challenging disturbance that requires proper clinical, radiological, and biomechanical evaluation, the treatment varies from case to another.

We should investigate every aspect of the case selected before taking any decision for the proper treatment, we conclude from the article that the best prognosis for uprighting an impacted second molar is when the root is at least one third of the full length.

References

1. Celebi A.A., Gelgor I.E., Catalbas B.: Correction of Mesially Impacted Lower Second Molar. *J Med Cases*. 2011;2: 236-239.
2. Freire-Maia B., Pereira T.J., Ribeiro M.P.: Distalization of impacted mandibular second molar using miniplates for skeletal anchorage- Case report. *Dental Press J Orthod*. 2011;16: 132-136
3. Shpack N., Finkelstein T., Lai Y.H., Kuftinec M.M., Vardimon A., Shapira Y.: Mandibular Permanent Second Molar Impaction Treatment options and outcome. *Open Journal of Dentistry and Oral Medicine*. 2013; 1: 9-14, 2013
4. Kaur M., Shefali S. Molar Impaction: Etiology, Implications and Treatment with Presentation of an Unusual Case. *Journal of Orofacial Research*. 2012;2: 171-173.
5. Po-Sung F.U., Chern-Hsiung L.A., Yi-Min W.U., Chinig-Fang T.S.: Uprighting impacted mandibular permanent second molars with the tip-back cantilever technique—cases report. *J Dent Sci*. 2008; 3: 174-180.
6. Sawicka M., Racka-Pilszaka B; Rosnowska-Mazurkiewicz A.: Uprighting Partially Impacted Permanent Second Molars. *Angle Orthodontist*. 2007; 77: 148-154.
7. Sivolella S., Roberto M., Bressan P., Bressan E., Cernuschi S., Miotti F., Berengo M.: Uprighting of the Impacted Second Mandibular Molar with Skeletal Anchorage. *Orthodontics – Basic Aspects and Clinical Considerations* pp. 247-265
8. Tinerfe T.J., Blakey G.H.: *Oral and maxillofacial surgery*. 2000
9. McAboy C.P., Grumet J.T., Siegel E.B., Iacopino A.M.: Surgical uprighting and repositioning of severely impacted mandibular second molars. *Journal of American Dental Association*. 2003; 134: pp. 1459– 1462.
10. Finotti M., Del Torre M., Roberto M., Miotti F.A. Could the distalization of the

- mandibular molars be facilitated? A new therapeutic method. *Orthodontie Francaise*. 2011; 80: 371-378.
11. Kokich VG, Mathews D.P.: Surgical and orthodontic management of impacted teeth. *Dent Clin North Am*. 1993;37:198–201.
12. Melsen B, Fiorelli G, Bergamini A.: Uprighting of lower molars. *J Clin Orthod*. 1996;30:640–645.
13. Giancotti A, Muzzi F, Santini F, Arcuri C. Miniscrew treatment of ectopic mandibular molar. *J Clin Orthod*. 2003;37: 380–383.