

See discussions, stats, and author profiles for this publication at: <https://www.researchgate.net/publication/6868244>

Clinical diagnosis of cutaneous leishmaniasis: A comparison study between standardized graded direct microscopy and ITS1-PCR...

Article in *Acta Tropica* · September 2006

DOI: 10.1016/j.actatropica.2006.07.001 · Source: PubMed

CITATIONS

55

READS

111

4 authors, including:



[Amer Al-Jawabreh](#)

LRU-Jericho

42 PUBLICATIONS 623 CITATIONS

[SEE PROFILE](#)



[Omar Hamarsheh](#)

Al-Quds University

41 PUBLICATIONS 382 CITATIONS

[SEE PROFILE](#)

Provided for non-commercial research and educational use only.
Not for reproduction or distribution or commercial use.



This article was originally published in a journal published by Elsevier, and the attached copy is provided by Elsevier for the author's benefit and for the benefit of the author's institution, for non-commercial research and educational use including without limitation use in instruction at your institution, sending it to specific colleagues that you know, and providing a copy to your institution's administrator.

All other uses, reproduction and distribution, including without limitation commercial reprints, selling or licensing copies or access, or posting on open internet sites, your personal or institution's website or repository, are prohibited. For exceptions, permission may be sought for such use through Elsevier's permissions site at:

<http://www.elsevier.com/locate/permissionusematerial>

Clinical diagnosis of cutaneous leishmaniasis: A comparison study between standardized graded direct microscopy and ITS1-PCR of Giemsa-stained smears

A. Al-Jawabreh^{a,b,*}, G. Schoenian^a, O. Hamarsheh^a, W. Presber^a

^a Institute of Microbiology and Hygiene, Charité University of Medicine, Dorotheenstr. 96, D-10098 Berlin, Germany

^b Leishmania Research Unit (LRU), P.O. Box 97, Jericho, Palestine

Received 10 August 2005; received in revised form 24 June 2006; accepted 4 July 2006

Available online 22 August 2006

Abstract

Parasitological diagnosis of cutaneous leishmaniasis is absolutely necessary before treatment. Direct microscopy of scrapings taken from the margins of skin lesions is the most commonly used method for clinical diagnosis of leishmaniasis. In this study to evaluate the usage of stained smears as samples for PCR and the possible advantage of PCR, we compared the sensitivity of the diagnosis of Giemsa-stained skin scrapings by standardized graded direct microscopy with that of ITS1-PCR with the material of the same area of the slide. Three 5 mm × 5 mm squares were marked on each of the 20 Giemsa-stained touch smears from 20 clinically diagnosed Palestinian patients. Out of the 60 squares scanned for amastigotes under 100× oil-immersion light microscopy, 45 (75%) gave usable results and 23 of these were positive for *Leishmania*. Fifteen (25%) squares could not be scanned microscopically, 12 because of staining that was too thick and 3 because of inadequate staining. DNA from each scanned square was extracted separately after microscopy and run through ITS1-PCR. Of the 23 microscopy-positive squares, 20 (87%) of these were positive by PCR. Of the three that were negative, one failed to extract for DNA, the second showed only one amastigote in the entire square, and the third was normally graded as +1 but was not amplified for unknown reasons. Of the 22 squares negative for microscopy, 18 (82%) were ITS1-PCR positive. Additionally, all three improperly stained squares were ITS1-PCR positive. Of the 12 darkly stained squares, 11 were positive. A negative control group of 15 German individuals from which Giemsa-stained slides containing three squares each was prepared and these slides were also microscopically scanned and tested by ITS1-PCR. Both tests were negative with both methods. Compared to microscopy (data in parenthesis), PCR showed a sensitivity of 87% (37%) and a specificity of 100% (100%). We have concluded that Giemsa-stained smears are a readily usable sampling method for PCR and that ITS1-PCR is far more sensitive than microscopy.

© 2006 Elsevier B.V. All rights reserved.

Keywords: Giemsa-stained smears; Standardized graded microscopy; ITS1-PCR; Jericho

1. Introduction

Cutaneous leishmaniasis (CL) in the Jericho area, or Jericho boil (Habat A'riha) as known by local inhabi-

tants, is a mainly zoonotic infection transmitted by the bite of the phlebotomine sandfly (Schlein et al., 1982, 1984) and caused by protozoan *Leishmania major* and *L. tropica* (Al-Jawabreh et al., 2004). CL is endemic and is a major health problem in Jericho (A'riha) and the adjacent hilly areas of Jerusalem (Al-Quds), Nablus, and Bethlehem with dozens of cases reported annually (Anis et al., 2001; Greenblatt et al., 1985; Al-Jawabreh et al.,

* Corresponding author. Tel.: +972 2 2321294; fax: +972 2 2321294.
E-mail address: islahjr@yahoo.com (A. Al-Jawabreh).

2003; Sawalha et al., 2003; Abdeen et al., 2002; Jaffe et al., 2004; MOH, 2004). The District of Jericho has been a very active CL focus for decades (De Beurmann, 1910; Huntmüller, 1914; Mastermann, 1914; Adler and Theodor, 1925; Canaan, 1945; Arda and Kamal, 1983).

In Jericho (A'riha) and its surrounding hilly areas, diagnosis of CL depends mainly on the clinical picture of the lesion. With improvements in medical laboratory infrastructure over the past decade it has been possible to introduce microscopy of Giemsa-stained touch smears as a parasitological diagnostic tool to visualize amastigotes. Due to the presence of other pathological conditions that mimic CL (Singh and Sivakumar, 2003) and the invasiveness, toxicity, and high cost of Pentostam treatment (Davidson, 1998; Hepburn, 2003), microscopy became adopted as protocol before treatment. Additionally, isolation of parasites using NNN media has been a routine diagnostic method since the late 1990s. Molecular methods including PCR-based techniques, which have gained momentum as highly sensitive and specific tests as they detect parasitic DNA, have been applied recently on a limited scale. PCR-based methods have provided the ability to both diagnose and also identify *Leishmania* species, which in some cases has consequences for treatment.

Several studies have compared conventional parasitological detection methods (i.e., microscopy, *in vitro* culture, and ELISA—enzyme-linked immunosorbent assay, in case of visceral leishmaniasis) with PCR-based methods. These studies were performed for the diagnosis of all forms of leishmaniasis – cutaneous leishmaniasis (CL), mucocutaneous leishmaniasis (MCL), and visceral leishmaniasis (VL) – using different types of specimens including dermal scrapings, whole blood, buffy coat, bone marrow aspirate, stained smears, skin biopsies, and formalin-fixed-paraffin-embedded tissue and serum (Piarroux et al., 1994; Momeni et al., 1996; Lachaud et al., 2000; Rodrigues et al., 2002; Medeiros et al., 2002; Motazedian et al., 2002; Reithinger et al., 2003; Fissore et al., 2004). Grading or scaling of microscopic examination has been used to check for parasite load in slides and subsequently in patients in the case of both VL and CL (WHO, 1999; Ramirez et al., 2000).

In this study, we evaluated the use of Giemsa-stained slides of skin scrapings from Palestinian patients that had been used for microscopy, as a potential sampling method for ITS1-PCR. This was done by assessing the sensitivity and rate of positivity of standardized graded microscopy with that of ITS1-PCR of Giemsa-stained skin scrapings. To our knowledge, no studies of this type have had a solution for the problem that a less sensitive method, microscopy—is the gold standard and therefore

tests with more sensitive and more specific methods that give differing results will be evaluated as false positive or false negative, respectively. To minimize this problem, we defined the Palestinian patients with typical ulcers as definitively positive and a group of German blood donors that had no history of leishmaniasis and had not been in any endemic area for at least 1 year as the negative group.

2. Materials and methods

2.1. Patients and study area

In the period between July 2002 and December 2003, a total of 86 patients living in the Jericho area of Palestine presenting skin lesions were referred to Islah Medical Laboratory-Jericho for diagnosis of CL by direct smear microscopy. Stratified random sampling was used to select 20 patients from the 86 for comparison with PCR. Of the 20 patients, 11 had microscopically positive samples (slides) and 9 were negative. As the rate of positivity for microscopy in Jericho is 30% (Al-Jawabreh et al., 2003), the 11 positives were an overrepresentation, but gave us the opportunity to select areas with different staining outcomes.

To check for the validity (sensitivity and specificity) of ITS1-PCR as a diagnostic test, 15 EDTA blood samples were obtained from the blood bank of the Charité Hospital, Berlin. These blood donors were all native Germans that had not visited a tropical country within the past year, had no history of leishmaniasis, had no typical skin ulcers, and tested negative for diseases routinely screened at the blood bank.

The patient profile represented by these samples corresponds to those patients seen at the laboratory: 50% (10/20) were children (<14), 40% (8/20) were adults (>14 years), and 10% (2/20) were of unknown age; 55% were male. Thirty-five percent of the patients (7/20) had only a single lesion, the same number had double lesions, and the remaining 30% (6/20) had multiple lesions (>3). The distribution of lesions was known in 44 cases and was as follows: 57% (25/44) on the head and neck, 39% (17/44) on the upper extremities, and 4.5% (2/44) on the lower extremities. Sixty-five percent (13/20) of the lesions were ≤ 1 month old, 10% (2/20) were 1–2 months old, and 15% (3/20) were 3 or more months old.

2.2. Sample collection and preparation

All tested patients showed typical lesions. These lesions were cleaned using sterile gauze and physiologic saline and disinfected five times in an outward circular motion with 70% alcohol-immersed cotton. Using a ster-




Fig. 1. Standardized grading microscopy: Giemsa-stained smears showing the three labeled 5×5 mm squares. Slide 777 prepared for microscopy with square 3 being purposefully selected as a darkly stained area. Slide 738 is a slide after the material has been scraped off and the DNA has been extracted.

ile lancet or sterile surgical blade, 2–3 mm long superficial incisions were made on the margins of the lesion and pressure was maintained with a finger to achieve hemostasis. From each patient, three touch smears of dermal tissue scrapings were collected, air-dried, fixed in absolute methanol, and Giemsa-stained.

2.3. Standardized graded microscopy

For all 20 Giemsa-stained slides selected for the comparative analysis, three $5 \text{ mm} \times 5 \text{ mm}$ squares were marked with a fine marker on the back surface of the slide and given the designations 1, 2, and 3 (Fig. 1). The size of the area marked corresponds to the area of approximately 600–1000 oil-immersion fields (OIF), as 1000 OIF per slide must be screened before declaring negative (World Health Organization, 1990). The squares were purposefully selected for marking on areas of differing density of the slide so as to have examples of the various outcomes of the staining procedure. Each square was completely scanned with an $100\times$ immersion lens by the same blinded person using the same bright-field microscopy (Fig. 1). A maximum of four slides were scanned daily to prevent exhaustion and related subjective interpretation. The average time taken to scan a $5 \text{ mm} \times 5 \text{ mm}$ square was 17.5 min. The number of amastigotes in each square was quantified and graded as compared to WHO grading used in splenic aspirate smears (World Health Organization, 1990) and the semi-quantitative scaling adopted by Ramirez et al. (2000) for touch smears from lesions of CL. The semi-quantitative grading to eval-

uate the parasitic density in each slide was performed as follows: grade/average of amastigotes/minimum of OIFs scanned: $-/0/625$ (whole square), $+/1$ amastigote per square to 1 per OIF/625 (whole square), $+/2$ –10 amastigotes per OIF/50, $+/3$ –20 amastigotes per OIF/50, and $+/4$ –>20 amastigotes per OIF/10.

The blood of the control group (German blood donors) was treated exactly the same: three squares were marked on each slide, DNA was extracted, PCR amplification for ITS1 was performed, and DNA extraction control for human β -actin housekeeping gene and the control panels were carried out.

2.4. PCR

2.4.1. Preparation of samples

The 20 selected slides contained 60 squares. DNA was extracted from each square as a separate sample. The immersion oil left from microscopy was gently wiped away using fine tissue paper. On the $5 \text{ mm} \times 5 \text{ mm}$ square, $50 \mu\text{l}$ of lysis buffer (50 mM NaCl, 50 mM ethylenediaminetetraacetic acid (EDTA) pH 7.4, 1% Triton X-100 and $200 \mu\text{g}$ proteinase K/ml) was applied to prevent loss of stained material when scraped off the slide using a fine spatula. The material was then aspirated and inserted into $200 \mu\text{l}$ of lysis buffer. The mixture was incubated for 3 h or overnight at 60°C . Lysates were then subjected to phenol–chloroform extraction (Van Eys et al., 1992; Meredith et al., 1993). The DNA pellets were dried using a speed vacuum dryer (savant, speedvac 100) for 5–10 min and re-dissolved in $100 \mu\text{l}$ TE buffer (10 mM Tris and 1 mM EDTA pH 7.5). To reduce the amount of possible inhibitors like hemoglobin and/or stain in clinical samples, the extracted DNA was then purified using Nucleospin[®] Extract (Macherey Nagel GmbH & Co. KG, Dueren, Germany). The $30 \mu\text{l}$ samples were kept at -20°C until used.

2.4.2. PCR amplification

A PCR was used to amplify the ribosomal internal transcribed spacer 1 (ITS1) region, which separates the genes coding for the ssu rRNA and L5.8S rRNA using the primers LITSR and L5.8S as described by El Tai et al. (2000) and Schoenian et al. (2003).

Approximately, $0.4 \text{ pg}/\mu\text{l}$ of DNA from the international reference strain of *L. turanica* (MRHO/MN/83/MNR-6) was used as positive control and sterile distilled water was used as the negative control as described by Schoenian et al. (2003).

A PCR inhibition control as described by Al-Jawabreh et al. (2004) was used in which $0.4 \text{ pg}/\mu\text{l}$ purified *L. turanica* DNA from cultured promastigotes was

run along each diagnostic sample. This was to recognize and overcome inhibitors found in clinical samples such as hemoglobin.

The β -actin primer pair *Aco1/Aco2* pair (5'-ACC TCA TGA AGA TCC TCA CC-3')/(5'-CCA TCT CTT GCT CGA AGT CC-3'), which targets a 120-bp fragment within the fourth exon of the human β -actin gene, was used as a DNA extraction control to check the integrity of DNA and therefore the true negativity of the ITS1-PCR under the same conditions described above for ITS1-PCR. All PCR negative were subjected to DNA extraction control (Musso et al., 1996).

To obtain enough material for subsequent restriction analysis, the ITS1-PCR products were re-amplified using the same primer combination and PCR conditions as for the first round of amplification.

2.5. Statistical analysis

McNemar's test was used to compare the matched pairs for graded microscopy and ITS1-PCR. McNemar's test was performed using the free Quickcalcs Web calculator available at <http://www.graphpad.com>.

Sensitivity and specificity of diagnostic tests employed in this study, ITS1-PCR, and graded microscopy, were calculated with samples from patients living in endemic areas (namely Jericho-Palestine) and showing typical lesion(s) for CL with compatible epidemiological history and from healthy German individuals.

3. Results

3.1. Positivity rates and sensitivities of ITS1-PCR and graded microscopy

Seventy-five percent (45/60) of the 5 mm \times 5 mm test squares could be scanned and graded for amastigotes microscopically (Fig. 1). The remaining 15 squares could not be scanned microscopically because of staining failure: in 12 cases the stain was too thick and in three cases the stain was too thin (see Table 2). These slides were considered negative. Table 1 shows that a parasite density of (+) in graded microscopy was observed in 21 squares; (++) in 2 squares; (–) in 22 squares thus 38% (23/60) were positive taking all samples into account and 52% (23/45) were positive if the badly stained slides are excluded; this (52%) can thus be considered the sensitivity of microscopy.

Of the 60 squares tested with ITS1-PCR, 52 were positive (87%) for leishmanial DNA (Table 2 and Fig. 2). The rate of positivity for ITS1-PCR among the 45

Table 1

Graded microscopy and ITS1-PCR results of patients' Giemsa-stained slides

Microscopy grades (no. of amastigotes)	No. of scanned squares	Microscopy results (positive)	ITS1-PCR positive
++ (2–10 per OIF)	2	2 (2)	2
+ (1 per square to 1 per OIF)	21	21 (21)	18 ^a
– (0 per square)	22	22 (0)	18
No microscopical evaluation possible ^b	15 ^b	0	14
Total	60	45 (23)	52

^a One sample is counted negative as a result of extraction failure.

^b Failure in staining did not allow microscopy.

Table 2

Comparison of the results of graded microscopy and ITS1-PCR for CL in the 60 square-test group

PCR (+)	PCR (–)	Total
Microscopy (+)		
20	2	23 ^a
	1 ^a	
Microscopy (–)		
18	4	37
3 poorly stained ^b		
12 darkly stained ^b	1	
Total		
52	8	60

^a One sample is counted negative as a result of extraction failure.

^b No microscopical examination possible due to failed staining.

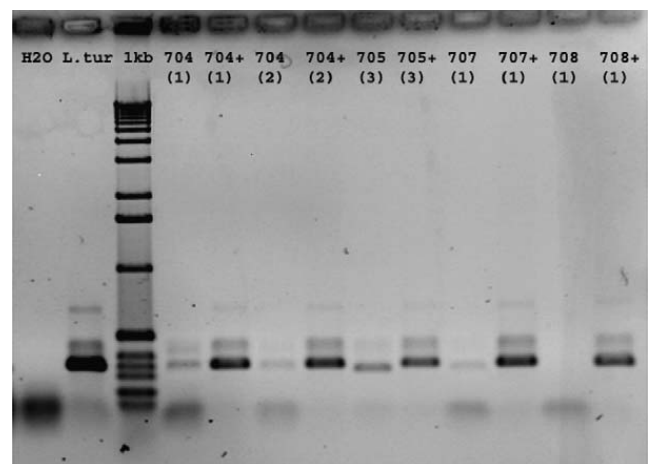


Fig. 2. PCR amplification of the 350 bp ITS1 region represented on 1.5% agarose gel. A 1 kb ladder is the molecular size marker. Numbers in brackets represent number of squares tested, while the (+) is the inhibition control. Samples 704(1), 704(2), 705(3), and 707(1) are positive while 708(1) is negative. The size difference between the bands is due to the presence of two species: *L. major* (335 bp) and *L. tropica* (319 bp).

squares screened by graded microscopy was also shown to be 87% (39/45), as shown by Table 1.

3.2. Statistical comparison of sensitivities

When comparing the results obtained by ITS1-PCR with those of graded microscopy, it was obvious that the improvement in diagnostic capability using ITS1-PCR is statistically very significant (McNemar's test, $P < 0.0013$). In the first group, or stratum, of the 23 squares that were positive by microscopy, 20 were ITS1-PCR positive (87%). Of the remaining three that were ITS1-PCR negative, one failed at the point of DNA-extraction, one showed only one amastigote in the whole square (more than 625 OIF) when examined by microscopy, and one was not quantified but rather was graded as +1 (Table 1). In the second group (22 microscopy negative squares), 18 were ITS1-PCR positive (82%) and 4 remained negative. Out of the 60 squares scanned for amastigotes under 100× oil-immersion bright-field microscopy, 15 (25%) squares could not be scanned due to improper staining. Of the 12 darkly stained squares, 11 were ITS1-PCR positive and one was PCR negative. The three poorly stained squares were all ITS1-PCR positive, thus 93% (14/15) of the slides for which microscopy failed were positive by PCR. The DNA extraction control in the ITS1-PCR negative probe was positive, ruling out extraction failure and indicating true negativity of PCR results from the extraction point of view.

The 45 squares that represented the 15 human negative controls were all negative by microscopy and ITS1-PCR. When merging the results of negative controls with those of the patient in 2 × 2 contingency tables, the sensitivity of microscopy becomes 37% (22/60) and specificity is 100% (Table 3).

In reality, one would attempt to prepare a new slide in the case of improper staining. We thus calculated the data of the sufficiently stained slides separately

(45). Microscopy then appears better: sensitivity is 49% (22/45) and specificity is 100% as shown in Table 3.

Comparing the results with ITS1-PCR, the advantage is obvious. Sensitivity becomes 87% (52/60) and specificity is 100% as shown in Table 3.

4. Discussion

The evaluation of a new diagnostic method in the absence of a valid or acceptable gold standard has always presented a dilemma particularly with regard to sensitivity. Quinnell et al. (2001) and Lachaud et al. (2002) have discussed the question of a gold standard. All conventional methods employed for the diagnosis of cutaneous leishmaniasis have modest to low rates of positivity. The positivity of microscopy was 42% according to Aviles et al. (1999); 46.7% according to Weigle et al. (2002); 48% according to Andresen et al. (1996); 67% according to Rodrigues et al. (2002). The positivity rate of histopathology was found to be 33% by Aviles et al. (1999), 76% by Andresen et al. (1996), and 66.2% by Rodrigues et al. (2002), who also found that of culture to be 46.5%. This broad range may be partly explained by varying parasite densities in different biological materials. Thus, Andresen et al. (1996) achieved the best results with histological sections (76%) and only 48% positivity in smears from ulcerations. Skin scrapings in comparison to other materials show heterogeneity with regard to the number of parasites per smear as the parasites are not equally distributed in the tissue and the number of cells fixed on the slide can also differ. More invasive sampling of specimens (biopsies versus scrapings) will improve the results.

To overcome the problem of gold standard, a broad case definition for CL was adopted, which depended on the presence of skin lesion(s), epidemiology of the area, and compatible clinical history of the patient. In this way we obtained the case group of Palestinians, all of whom presented typical lesions and lived in an endemic area with high probability of becoming infected.

In leishmaniasis diagnostics, the real problem is to find a highly sensitive method to correctly diagnose cases with only few parasites in the material. In this study, if we consider the demonstration of amastigotes in a stained smear as the 'gold standard' (WHO, 1999) the ITS1-PCR proved more sensitive (87%) compared to graded microscopy (37% or 49% using only the correctly stained samples). The fact that there were no positive PCR reactions in the negative group and negative controls were always negative confirmed the real positivity of the PCR results.

Table 3
Sensitivity and specificity of microscopy using a negative control group

	CL (+)	CL (–)	Total
Microscopy (+)	22	0	22
Microscopy (–)	38 ^a (23) ^b	45	83 ^a (68) ^b
Total microscopy	60 ^a (45) ^b	45	105 (90) ^b
PCR (+)	52	0	52
PCR (–)	8	45	53
Total PCR	60	45	105

^a Including the 15 staining failures.

^b Without staining failures.

In general, the sensitivity of ITS1-PCR is in good agreement with that of other studies that evaluated microscopy and PCR-based methods. Sensitivity ranged from 75.7% to 100% depending on the DNA target amplified (i.e., kinetoplast DNA, ribosomal RNA genes, minicircle DNA), the specificity of primers (genus-, subgenus-, or species-specificity), and the nature of clinical specimens (Piarroux et al., 1994; Andresen et al., 1996; Belli et al., 1998; Aviles et al., 1999; Weigle et al., 2002; Rodrigues et al., 2002; Motazedian et al., 2002; Medeiros et al., 2002). Thus, also in case of PCR, the result depends on the material and choosing the right material may improve the results.

In this study, the same area of Giemsa-stained slides, and thus the same quantities of clinical material, were analyzed by both graded microscopy and ITS1-PCR for the first time. This allowed subsequent statistical analyses of matched pairs, which was meant to strengthen and validate the comparison process. Furthermore, a control group from a non-endemic area was introduced.

ITS1-PCR as a diagnostic test for skin scrapings was clearly advantageous over graded microscopy in its increased sensitivity. Most of the clinically positive cases that were graded as negative by microscopy were positive by PCR, which makes grading, particularly (–) and (+1), invalid as a diagnostic tool. Procedural mishaps such as excessive or inadequate staining did not prevent diagnosis by ITS1-PCR, which eliminates the need for re-sampling and thus saves time, effort, and materials. It is likely time to replace microscopy as the “gold standard” of leishmaniasis diagnostics with PCR assuming that the lab has the appropriate expertise to perform PCR and that all precautions to avoid carry-over contamination are taken.

This study also showed that Giemsa-stained slides used for diagnosis with microscopy could readily be used as samples for diagnosis with PCR. ITS1-PCR-based techniques offer a very sensitive method for the diagnosis of CL using Giemsa-stained smears as compared to graded microscopy similar to that adopted by the WHO for VL (WHO, 1999). The genus-specific PCR primer pair used in this study (El Tai et al., 2000) makes it possible not only to diagnose leishmaniasis directly, but also to differentiate all relevant Old World species of *Leishmania* including *L. major* and *L. tropica*, which predominate in the district of Jericho-Palestine (Al-Jawabreh et al., 2004). Nonetheless, in addition to negative and positive controls containing distilled water and *Leishmania* DNA, respectively, inhibition and DNA extraction controls should be included for every sample analyzed to ensure reliability and validity of the amplification reaction. The challenge that remains is to make ITS1-PCR,

and PCR-based methods in general, more economically and technically attractive in regions of high endemicity and to bring them from research institutions into routine clinical use.

References

- Abdeen, Z.A., Sawalha, S.S., Eisenberger, C.L., Khanfar, H.M., Greenblatt, C.L., Yousef, O., Schnur, L.F., Azmi, K., Warburg, A., Bader, K.A., Jaffe, C.L., Baneth, G., 2002. Epidemiology of visceral leishmaniasis in the Jenin District, West Bank: 1989–1998. *Am. J. Trop. Med. Hyg.* 66, 329–333.
- Adler, S., Theodor, O., 1925. The experimental transmission of cutaneous leishmaniasis to man from *Phlebotomus papatasi*. *Ann. Trop. Med. Parasitol.* 19, 365–371.
- Al-Jawabreh, A., Schnur, L.F., Nasereddin, A., Schwenkenbecher, J.M., Abdeen, Z., Barghuthy, F., Khanfar, H., Presber, W., Schoenian, G., 2004. The recent emergence of *Leishmania tropica* in Jericho (A'riha) and its environs, a classical focus of *Leishmania major*. *Trop. Med. Int. Health* 9 (7), 812–816.
- Al-Jawabreh, A., Barghuthy, F., Schnur, L.F., Jacobson, R.L., Schoenian, G., Abdeen, Z., 2003. Risk assessment of cutaneous leishmaniasis in the endemic area of Jericho in Palestine. *East Mediterr. Health J.* 9 (4), 805–815.
- Andresen, K., Gaafar, A., El-Hassan, A.M., Ismail, A., Dafalla, M., Theander, T.G., Kharazmi, A., 1996. Evaluation of the polymerase chain reaction in the diagnosis of cutaneous leishmaniasis due to *Leishmania major*: a comparison with direct microscopy of smears and sections from lesions. *Trans. R. Soc. Trop. Med. Hyg.* 90 (2), 133–135.
- Anis, E., Leventhal, A., Elkana, Y., Wilamowski, A., Pener, H., 2001. Cutaneous leishmaniasis in Israel in the era of changing environment. *Pub. Health Rev.* 29, 37–47.
- Arda, H.M., Kamal, A., 1983. A report on cutaneous leishmaniasis in the West Bank of Jordan. *Jordan Med. J.* 17, 57–63.
- Aviles, H., Belli, A., Armijos, A., Monroy, F.P., Harris, E., 1999. PCR detection and identification of *Leishmania* parasites in clinical specimens in Ecuador: a comparison with classical diagnostic methods. *J. Parasitol.* 85 (2), 181–187.
- Belli, A., Rodriguez, B., Aviles, H., Harris, E., 1998. Simplified polymerase chain reaction detection of new world leishmania in clinical specimens of cutaneous leishmaniasis. *Am. J. Trop. Med. Hyg.* 58 (1), 102–109.
- Canaan, T., 1945. Topographical studies in leishmaniasis in Palestine. *J. Palest. Arab Med. Ass.* 1, 4–12.
- Davidson, R.N., 1998. Practical guide for the treatment of leishmaniasis. *Drug* 56, 1009–1018.
- De Beurmann, 1910. Leishmaniosis ulcerosa cutis un cas de bouton des pays chauds contracte a Jericho. *Rev. Med. Hyg. Trop.* 7, 265–271.
- El Tai, N.O., Osman, O.F., El Fari, M., Presber, W., Schoenian, G., 2000. Genetic heterogeneity of ribosomal internal transcribed spacer (ITS) in clinical sample of *Leishmania donovani* spotted on filter paper as revealed by single-strand conformation polymorphisms (SSCP) and sequencing. *Trans. R. Soc. Trop. Med. Hyg.* 94, 75–79.
- Fissore, C., Delaunay, P., Ferrua, B., Rosenthal, E., Del Giudice, P., Aufeuvre, J.-P., Le Fichoux, Y., Marty, P., 2004. Convenience of serum for visceral leishmaniasis diagnosis by PCR. *J. Clin. Microbiol.* 42 (11), 5332–5333.
- Greenblatt, C.L., Schlein, Y., Schnur, L.F., 1985. Leishmaniasis in Israel and vicinity. In: Chang, K.-P., Bray, R.S. (Eds.), *Human*

- Parasitic Diseases, Leishmaniasis, vol. 1. Elsevier, Amsterdam, pp. 415–426.
- Hepburn, N.C., 2003. Cutaneous leishmaniasis: an overview. *J. Postgrad. Med.* 49 (1), 50–54.
- Huntemüller, 1914. Neuartige Parasitenbefunde bei der Jerichobeule. *Centralbl. F. Bakt., Abt. I. Orig. Bd.* 73, 137–141.
- Jaffe, C.L., Baneth, G., Abdeen, Z.A., Schlein, Y., Warburg, A., 2004. Leishmaniasis in Israel and the Palestinian authority. *Trends Parasitol.* 20 (7), 328–332.
- Lachaud, L., Dereure, J., Chabbert, E., Jacques, R., Mauboussin, J.M., Oziol, E., Dedet, J.P., Bastien, P., 2000. Optimized PCR using patient blood samples for diagnosis and follow-up of visceral leishmaniasis, with special reference to AIDS patients. *J. Clin. Microbiol.* 38 (1), 236–240.
- Lachaud, L., Chabbert, E., Dubessay, P., Dereure, J., Lamothe, J., Dedet, J.P., Bastien, P., 2002. Value of two PCR methods for the diagnosis of canine visceral leishmaniasis and the detection of asymptomatic carriers. *Parasitology* 125 (3), 197–207.
- Mastermann, E.W.G., 1914. Notes on some tropical diseases in Palestine. *J. Hyg.* 14, 1–11.
- Medeiros, A.C.R., Rodrigues, S.S., Roselino, A.M.F., 2002. Comparison of the specificity of PCR and the histopathological detection of leishmania for the diagnosis of American cutaneous leishmaniasis. *Braz. J. Med. Biol. Res.* 35, 421–424.
- Meredith, S.E.O., Zijlstra, E.E., Schoone, G.J., Kroon, C.C., Van Eys, G.J., Schaeffer, K.U., El-Hassan, A.M., Lawyer, P.G., 1993. Development and application of the polymerase chain reaction for the detection and identification of Leishmania parasites in clinical material. *Arch. Inst. Pasteur Tunis.* 70, 419–431.
- Momeni, A.Z., Yotsumoto, S., Mehregan, D.R., Mehregan, A.H., Mehregan, D.A., Aminjavaheri, M., Fujiwara, H., Tada, J., 1996. Chronic lupoid leishmaniasis. Evaluation by polymerase chain reaction. *Arch. Dermatol.* 132 (2), 198–202.
- Motazedian, H., Karamian, M., Noyes, H.A., Ardehali, S., 2002. DNA extraction and amplification of Leishmania from archived, Giemsa-stained slides, for the diagnosis of cutaneous leishmaniasis by PCR. *Ann. Trop. Med. Parasitol.* 9 (1), 31–34.
- Musso, O., Sommer, P., Drouet, E., Cotte, L., Neyra, M., Grimaud, J., Chevallier, M., 1996. *In situ* detection of human cytomegalovirus DNA in gastrointestinal biopsies from AIDS patients by means of various PCR-derived methods. *J. Vir. Meth.* 56, 125–137.
- Piarroux, R., Gambarelli, F., Dumon, H., Fontes, M., Dunan, S., Mary, C., Toga, B., Quilici, M., 1994. Comparison of PCR with direct examination of bone marrow aspiration, myeloculture, and serology for diagnosis of visceral leishmaniasis in immunocompromised patients. *J. Clin. Microbiol.* 32 (3), 746–749.
- Quinnell, R.J., Courtenay, O., Davidson, S., Garcez, L., Lambson, B., Ramos, P., Shaw, J.J., Shaw, M.A., Dye, C., 2001. Detection of *Leishmania infantum* by PCR, serology and cellular immune response in a cohort study of Brazilian dogs. *Parasitology* 122 (3), 253–261.
- Ramirez, J.R., Agudelo, S., Muskus, C., Alzate, J.F., Berbrich, C., Barker, D., Velez, I.D., 2000. Diagnosis of cutaneous leishmaniasis in Colombia: the sampling site within lesions influences the sensitivity of parasitologic diagnosis. *J. Clin. Microbiol.* 38 (10), 3768–3773.
- Reithinger, R., Espinoza, J.C., Courtenay, O., Davis, C.R., 2003. Evaluation of PCR as a diagnostic mass-screening tool to detect *Leishmania (Viannia)* spp. in domestic dogs (*Canis familiaris*). *J. Clin. Microbiol.* 41 (4), 1486–1493.
- Rodrigues, E.H.G., de Brito, M.E.F., Mendonca, M.G., Werkhäuser, R.P., Coutinho, E.M., Souza, W.V., de Albuquerque, M.F.P.M., Jardim, M.L., Abath, F.G.C., 2002. Evaluation of PCR of American cutaneous leishmaniasis in an area of endemicity in northeastern Brazil. *J. Clin. Microbiol.* 40 (10), 3572–3576.
- Sawalha, S.S., Shtayeh, M.S., Khanfar, H.M., Warburg, A., Abdeen, Z.A., 2003. Phlebotomine sand flies (Diptera: Phlebotomidae) of the Palestinian West Bank: potential vectors of leishmaniasis. *J. Med. Entomol.* 40, 321–328.
- Schlein, Y., Warburg, A., Schnur, L.F., Gunders, A.E., 1982. Leishmaniasis in the Jordan Valley II. Transmission in the central endemic area. *Trans. R. Soc. Trop. Med. Hyg.* 76 (5), 582–586.
- Schlein, Y., Warburg, A., Schnur, L.F., Le Blancq, S.M., Gunders, A.E., 1984. Leishmaniasis in Israel: reservoir host, sandfly vectors and leishmanial strains in the Negev, Central Arava and along the Dead Sea. *Trans. R. Soc. Trop. Med. Hyg.* 78, 480–484.
- Schoenian, G., Nasereddin, A., Dinse, N., Schweynoch, C., Schallig, H.D., Presber, W., Jaffe, C.L., Dinse, N., 2003. PCR diagnosis and characterization of *Leishmania* in local and imported clinical samples. *Diagn. Microbiol. Infect. Dis.* 47, 349–358.
- Singh, S., Sivakumar, R., 2003. Recent advances in the diagnosis of leishmaniasis. *J. Ind. Postgrad., Med.* Online full text at <http://www.jpgmonline.com>.
- Van Eys, G.J.J.M., Schoone, G.J., Kroon, N.C.M., Ebeling, S.B., 1992. Sequence analysis of small subunit ribosomal RNA genes and its use for detection and identification of *Leishmania* parasites. *Mol. Biochem. Parasitol.* 51, 133–142.
- Weigle, K.A., Labrada, L.A., Lozano, L., Santrich, C., Barker, D.C., 2002. PCR-based diagnosis of acute and chronic cutaneous leishmaniasis caused by *Leishmania (Viannia)*. *J. Clin. Microbiol.* 40.2, 601–606.
- WHO Recommended Surveillance Standards; 1999. 2nd ed., WHO/CDS/CSR/ISR/99.2.
- World Health Organization, Control of the Leishmaniasis, WHO Tech. Rep. Ser, vol. 753, 1990. p. 154.