

## Tooth Autotransplantation in Orthodontic Patients

Jawad A. Abu Tair, DMD; Ahmad Rahhal, DDS, PhD

### Abstract

**Aim:** The aims of this report are to present three cases of autotransplantation along with a review of the indications, selection criteria for patient donor and recipient sites, and the major steps in the surgical procedure.

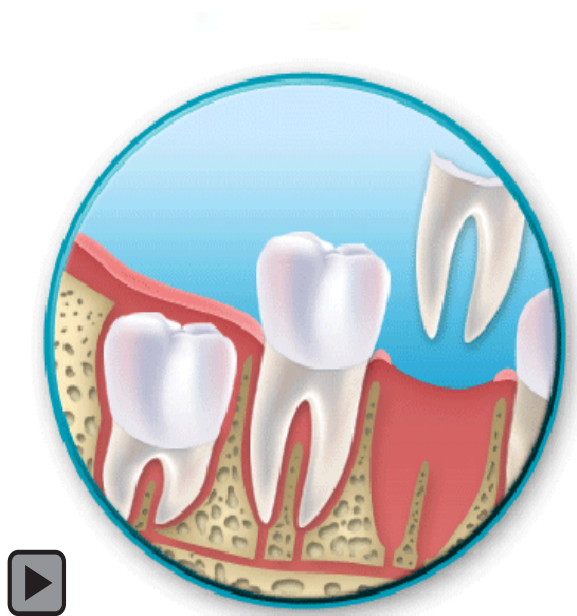
**Background:** Autogenous tooth transplantation, or autotransplantation, is the surgical movement of a tooth from one location in the mouth to another in the same individual. It can be a good treatment option in many cases if the dentist knows the implications, indications, and contraindications.

**Case Descriptions:** Three cases with different treatment indications and plans are presented. All showed autotransplantation of teeth as part of orthodontic treatment. It emphasized the benefits of this treatment modality such as new bone formation and lower costs. One case, a rare example of multiple congenitally missing teeth treated by autotransplantation, also was presented.

**Summary:** As shown in these case reports, there are instances where the autotransplantation of teeth is appropriate and may possibly simplify future planned orthodontic or prosthodontic treatment.

**Clinical Significance:** Tooth autotransplantation is an easy and good treatment option, applicable in a lot of cases, substituting different types of prostheses, including dental implants.

**Keywords:** Tooth autotransplantation, autogenous tooth transplantation, congenitally missing teeth, orthodontic.



**Citation:** Abu Tair JA, Rahhal A. Tooth Autotransplantation in Orthodontic Patients. *J Contemp Dent Pract* [Internet]. 2010 May; 11(3):063-070. Available from: [http://www.thejcdp.com/journal/view/volume11-issue3-abu\\_tair](http://www.thejcdp.com/journal/view/volume11-issue3-abu_tair).

### Introduction

Transplantation of teeth in humans is not a recently established surgical procedure. Ambroise Pare appears to have been the first to publish a report about transplantation of teeth in 1554.<sup>1</sup> Autotransplantation of teeth is a treatment option in cases of agenesis, ectopic eruption, trauma, destructed teeth, or other pathology.<sup>2</sup> The benefits of autotransplantation over other treatment options are numerous. The transplanted tooth can regenerate bone, unlike the dental

implant, which often requires bone grafting to fulfill all necessary functional and esthetic demands. Autogenous dental transplantation is also about 87 percent less costly than a dental implant, an obvious benefit to most patients.<sup>3</sup> Autogenous transplantation also can be performed in patients who are not yet fully grown because the transplant is actively growing and developing with the patient and not passively locked into position as is an endosseous dental implant.<sup>3</sup> Also autotransplanted teeth are better substitutes than fixed or removable prostheses. Disadvantages include the invasiveness of surgery and the possibility of failure, although the procedure is usually no more traumatic for the patient than the removal of impacted third molars. The most apparent restriction to autogenous transplantation is the limited supply of available donor teeth.

Andreasen et al.<sup>4</sup> noted that continued root development and pulpal healing can be expected in developing transplanted teeth. In their view, the optimum stage for autotransplantation is when three-quarters of the root has formed, in stage 3-4 of dental development (according to Moorrees et al.).<sup>5</sup> The technique also can be successful with completely formed roots, but such teeth will eventually need root canal therapy.<sup>5</sup> In cases of tooth germ transplantation, the follicle, if possible, should be kept intact. Whenever possible the tooth germs are transplanted to their normal level in the alveolar process according to their stage of root development, under the mucous membrane and retained with interrupted sutures.<sup>6</sup>

### Patient Selection Criteria:

Candidates must:

- Be in good health,
- Be able to follow post-operative instructions,
- Be available for follow-up visits,
- Be able to demonstrate an acceptable level of oral hygiene, and
- Have a suitable recipient site and donor tooth.

### Recipient Site Criteria<sup>2</sup>

- There must be adequate bone support in all dimensions.
- There must be adequate attached keratinized tissue.
- Recipient site should be free from acute infection. On the other hand, chronic infection (including periapical granuloma, or infected

cyst), if present, should be carefully removed from the recipient site.

### Donor Tooth Criteria<sup>2</sup>

- The donor tooth should resemble the recipient site in main morphological features; e.g., maxillary second premolar or mandibular premolars to be transplanted in maxillary central incisor socket.
- Teeth with either open or closed apices may be donors.
  - **Open apices teeth:**
    - The most predictable results are obtained with teeth having between one-half and two-thirds completed root development.
    - A tooth with an open apex will remain vital and should continue root development after transplantation.
  - **Closed apices teeth:**
    - Tooth with complete or near complete root formation will generally require root canal therapy (RCT).
    - It is recommended that endodontic treatment be completed prior to donor tooth extraction (i.e., to treat the donor tooth endodontically by a complete RCT before the transplantation procedure).

### Success

According to Jonsson and Sigurdsson,<sup>7</sup> the rate of pulp survival in transplants with partly formed roots is 66 percent, with the anticipation of continued root growth and normal apical closure, but the overall success rate of autotransplantation was 92.5 percent. The literature includes reports with excellent success rates following tooth transplantation when the appropriate protocol is followed. Andreasen et al.<sup>8</sup> found 95 percent and 98 percent long-term survival rates for incomplete and complete root formation of 370 transplanted premolars observed over 13 years. Kugelberg et al.<sup>9</sup> achieved success rates of 96 percent and 82 percent for 45 immature and mature teeth transplanted into the maxillary incisor region over four years. Lundberg and Isaksson<sup>10</sup> had success in 94 percent and 84 percent of cases for open and closed apices respectively in 278 autotransplanted teeth over five years. Cohen et al.<sup>11</sup> showed success in the ranges of 98 to 99 percent over five years and 80 to 87 percent over 10 years with transplanted anterior teeth with closed apices. Nethander<sup>12</sup> found five-year success rates of over

90 percent for 68 mature teeth transplanted with a two-stage technique. Josefsson et al.<sup>13</sup> found four-year success rates of 92 percent and 82 percent respectively for premolars with incomplete and complete root formation.

## Case Descriptions

In this article three cases are presented, illustrating the different applications of tooth autotransplantation as a treatment modality. The first case shows the main surgical steps of tooth autotransplantation in place of heavily destructed first molars. The later two cases show the application as a treatment modality in orthodontic patients.

### Case 1

A 16-year-old healthy female patient attended the orthodontic clinic, complaining of minor crowding in her lower teeth. She was referred to the surgery clinic for extraction of grossly carious teeth, the lower left second permanent molar and the lower right first permanent molar (Figure 1).

She also had two lower third molars with one-third to one-half of the roots developed. The rehabilitation options after the extraction of grossly carious teeth were (1) dental implants and crowns or (2) a fixed partial denture on the mandibular right side and inclined eruption of the left third

molar into the place of the extracted second molar. A third option was autotransplantation of the third molars to the extraction sites.

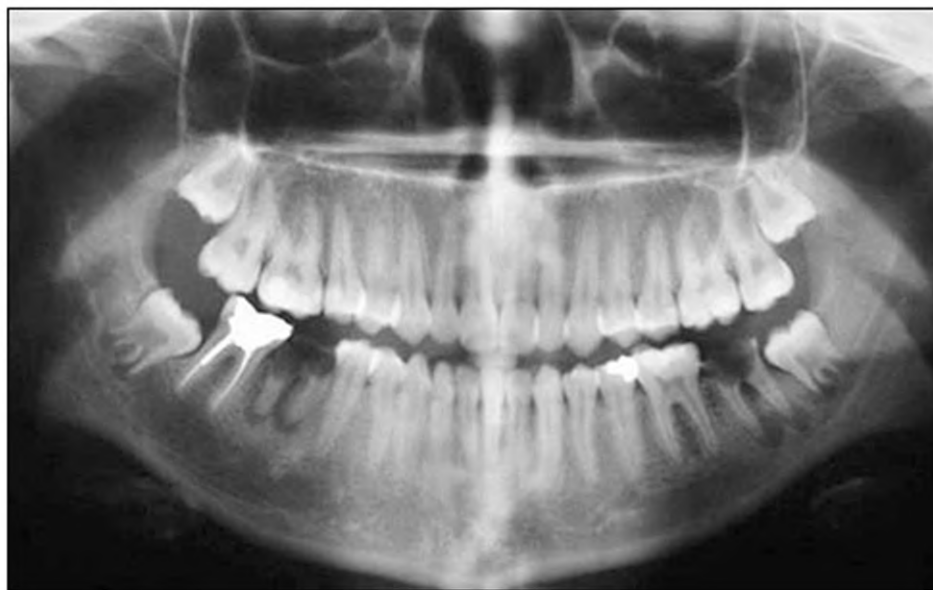The final treatment plan was to do autotransplantation of the third molars to the intended extraction sites in the same appointment.

Extraction of the indicated teeth—the mandibular right first molar (Figure 2) and the mandibular left second molar (Figure 3)—was performed. Then the sockets at the extraction site were cleaned by curettage, followed by a normal saline irrigation (Figure 4).

The third molars were exposed by a flap that resembled an extraction flap and gently extracted (Figures 5 and 6). The cervical tissue under the cemento-enamel junction was not traumatized intentionally to decrease the possibility of future root ankylosis.

The donor teeth were inserted into the extraction sites, one on each side, after minor trimming of the bulgy enamel so the teeth fit deep into each socket and out of occlusion. Both teeth were splinted in their new place using figure eight 3/0 black silk sutures (Figures 7, 8, 9).

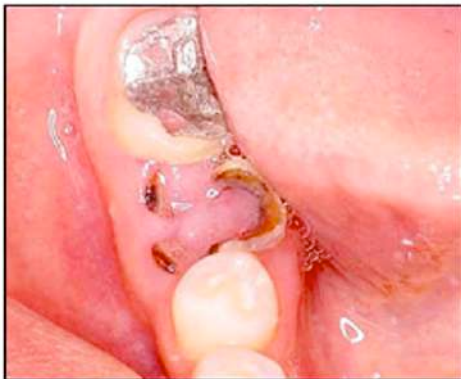Amoxicillin 500 mg, three times daily for five days, was the antibiotic given to the patient postoperatively to prevent infections. The sutures



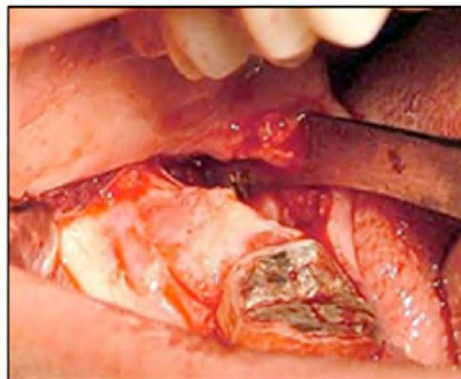**Figure 1.** Destructed lower right first and left second molars, with periapical lesions.

were removed one week later, and follow-up radiographs were taken immediately, at three months (Figures 10 and 11), and one year later. The teeth have now been in the transplanted

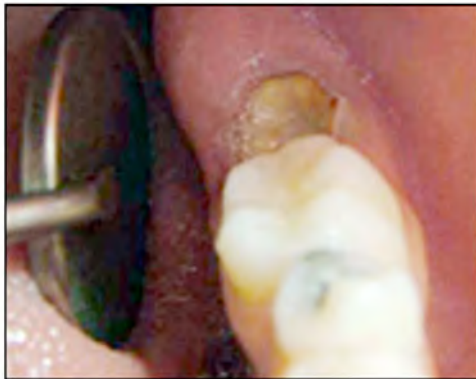sites for three years with normal stability. They are vital and in good periodontal health. The roots continued to develop.



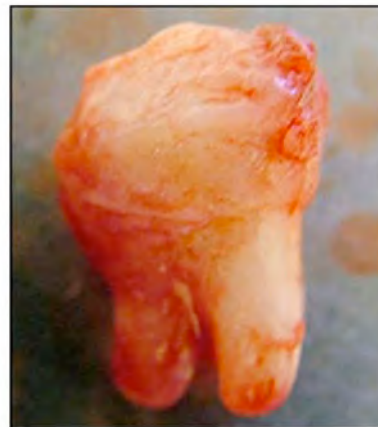**Figure 2.** Preoperative view of the mandibular right first molar.



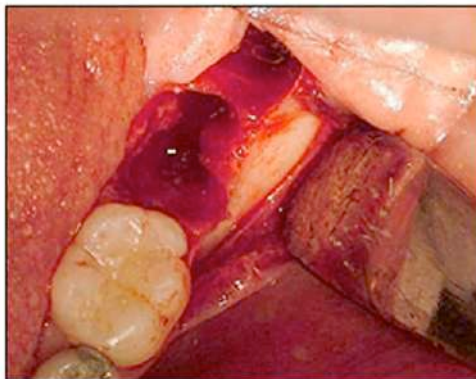
**Figure 5.** Exposure of the mandibular right third molar follicle.



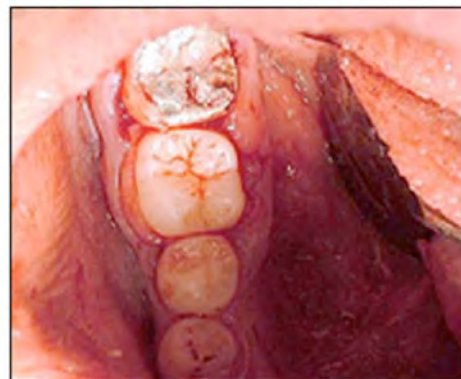**Figure 3.** Preoperative view of the mandibular left second molar.



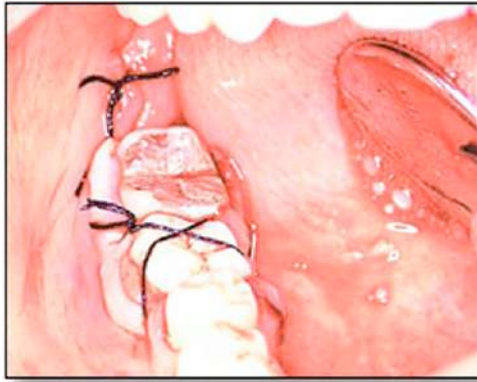
**Figure 6.** Third molar with the follicular tissue preserved.



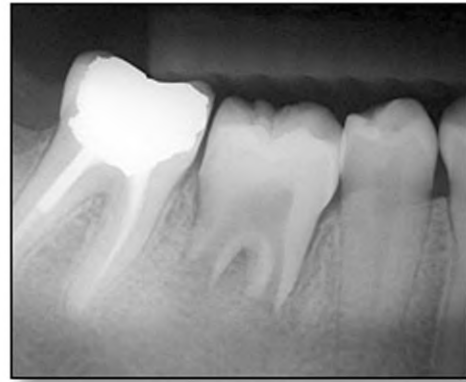
**Figure 4.** Extraction socket after curettage and irrigation of mandibular left second molar.



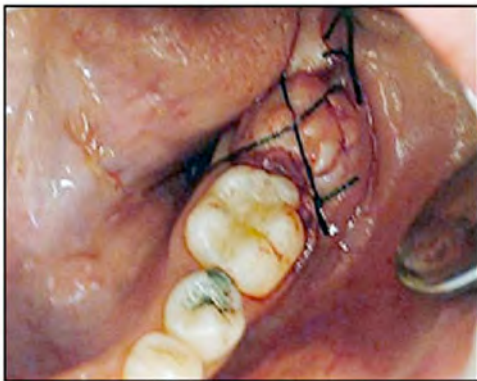**Figure 7.** Mandibular right third molar in socket of first molar tooth.



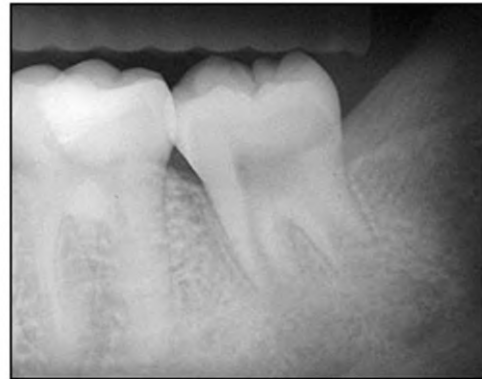**The tooth** was splinted out of occlusion with the help of figure eight suture.



**One year** after transplantation to first molar site.



**Figure 9.** Mandibular left third molar splinted in its new location with a suture.



**Figure 11.** One year after transplantation to second molar site.

## Case 2

This case report describes the use of tooth autotransplantation in an orthodontic patient with a horizontally impacted second molar, difficult for orthodontic traction.

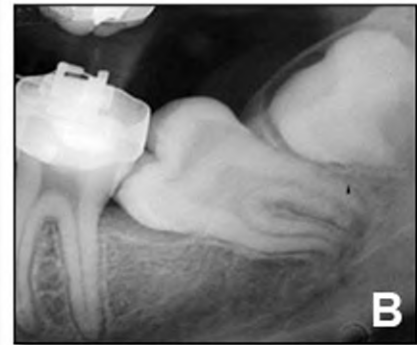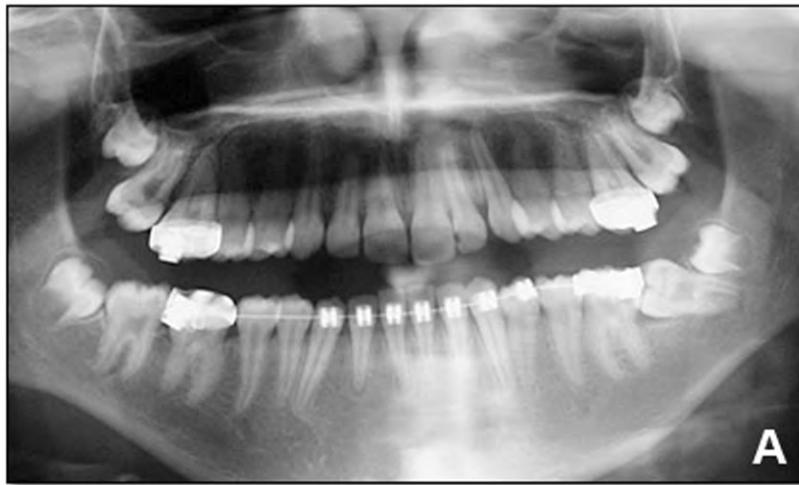
A 13-year-old female was seen in the orthodontic clinic for a consultation regarding mild crowding of her mandibular anterior teeth. On examination, the orthodontist noticed a partially impacted lower left permanent second molar. Radiographic examination showed a horizontally impacted second molar with near contact of its occlusal surface with the distal surface of the first molar. The third molar follicle was seen with stage 1 development, according to Moorrees et al.<sup>5</sup> staging. (Figure 12)

Several treatment options were considered: extraction of the third molar and then uprighting of the partially impacted second molar. But this

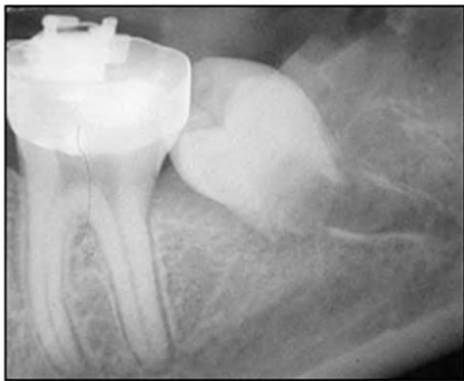
treatment would be difficult and risky to undertake. The second option was to extract both the second and third molars and later to insert a dental implant to replace the missing second molar. The third option was to do autotransplantation of the third molar follicle to the site of the second molar.

The third treatment option was selected in this case. During the procedure, extraction of the second molar was done with preservation of bone in the area. The third molar follicle was harvested, with preservation of the follicular sac, and transplanted to the socket of the second molar. The flap was closed primarily without interference of the soft tissue with the opposing teeth.

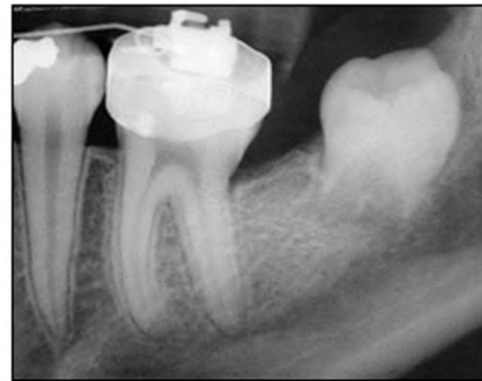An immediate postoperative periapical radiograph showed mesial angulation of the tooth follicle after transplantation. So immediate alignment was done the same day, without excessive effort for the surgeon or the patient (Figures 13 and 14).



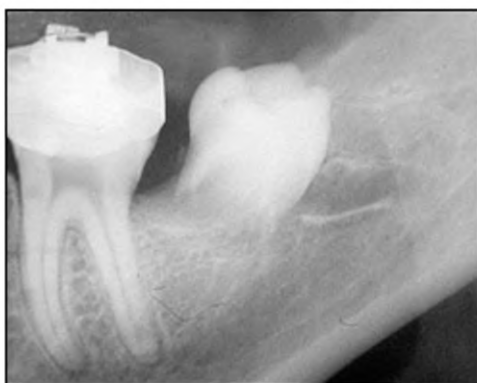**Figure 12. A.** Panoramic radiograph shows the alignment of both mandibular left second and third molars. **B.** The periapical radiograph shows clearly the bone level distal to the second molar, and the first stage of root development of the third molar.



**Figure 13.** Immediate postoperative radiograph, showing mesial angulation of the transplanted follicle.



**Figure 15.** One year after transplantation, minor development of the roots was noted.

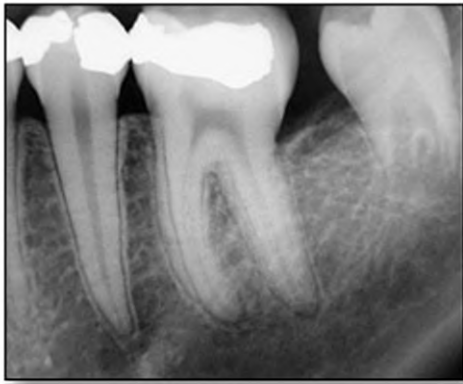

**Figure 14.** Alignment of the third molar follicle done in the same session.

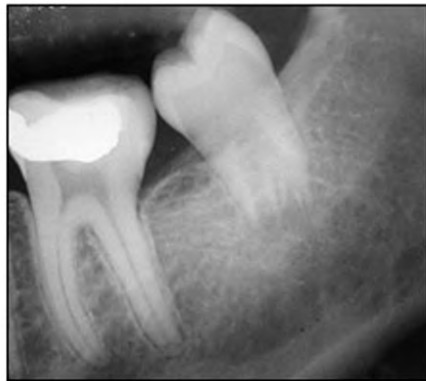Antibiotic coverage was prescribed (Amoxicillin 500 mg, three times daily for five days), and sutures were removed one week later.

One year later we began to notice changes related to the root development and follicle angulation in the new position (Figure 15).

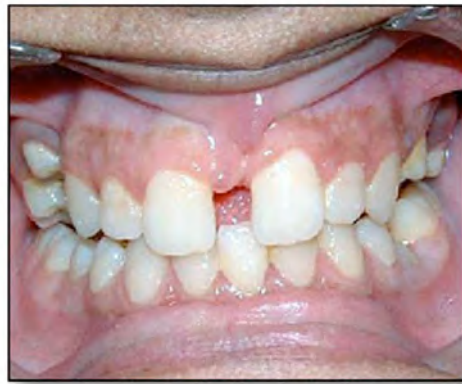The tooth continued to develop, and erupted about two and half years after its transplantation. It continued to erupt until it was in complete occlusion with the opposing tooth (Figures 16 and 17). Note the new bone formation around the root of the erupting tooth.



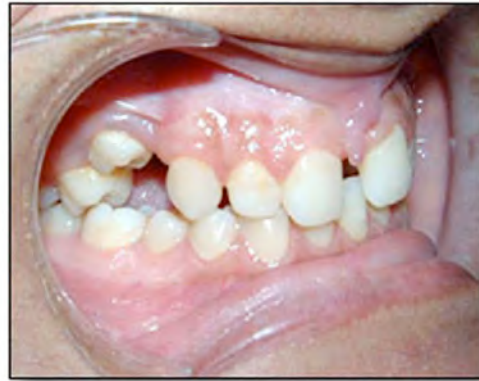**Two years** after transplantation, showing good root development.



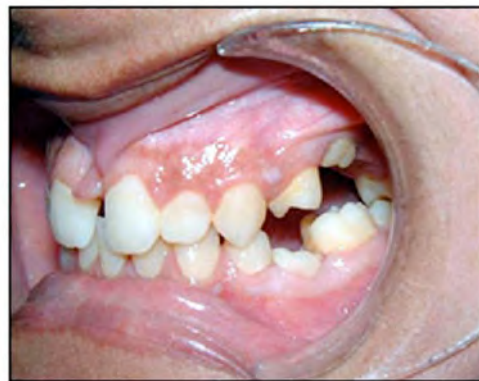**Figure 17.** Three years after transplantation showing both root and bone development.



**Figure 18.** Central diastema and retained right second deciduous molar.



**Figure 19.** Note the retained right second deciduous molar.



**Figure 20.** Note the retained maxillary left first deciduous molar and the mandibular left second deciduous molar.

### Case 3

In this case autotransplantation of teeth in place of congenitally missing premolars is presented.

A 16-year-old female patient was seen in the orthodontic clinic with a chief complaint of teeth spacing and improper occlusion. On both clinical and radiological examination, the maxillary right second deciduous molar, the maxillary left first deciduous molar, and the mandibular left second deciduous molar were retained but out of the occlusal plane. The maxillary right first and second premolars, the maxillary left second premolar, and the mandibular left second premolar were congenitally missing. The maxillary left first molar had been recently extracted due to gross caries. Note the spacing between the teeth (anterior diastema) (Figures 18–21).

The maxillary left first premolar was extracted by mistake when she was referred to her

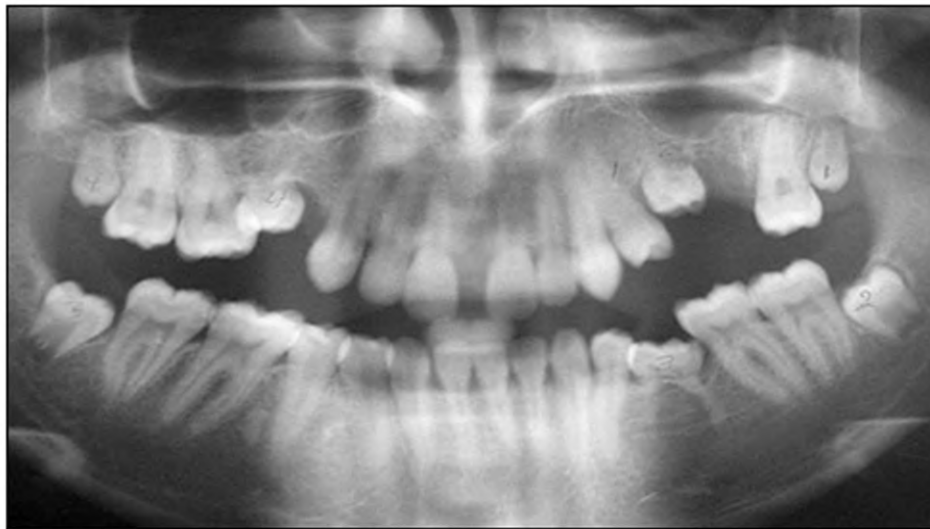dentist for extracting the maxillary left first deciduous molar; this complicated the case and raised the possibility of autotransplantation of the third molars to the missing teeth areas. The morphology of the maxillary third molars resembles the premolars, which helped in decision making.

Under general anesthesia, the maxillary right second deciduous molar was extracted and the third molar of the same side was transplanted to the fresh socket. Also the maxillary left third molar was transplanted to the socket of the maxillary left first premolar, and the mandibular left third molar was transplanted to the place of the maxillary left first molar. The mandibular left second deciduous molar also was extracted, and the mandibular right third molar was transplanted into its socket. In all the recipient sites, minor preparations of the alveolar bone were made to accommodate the morphology of the transplanted

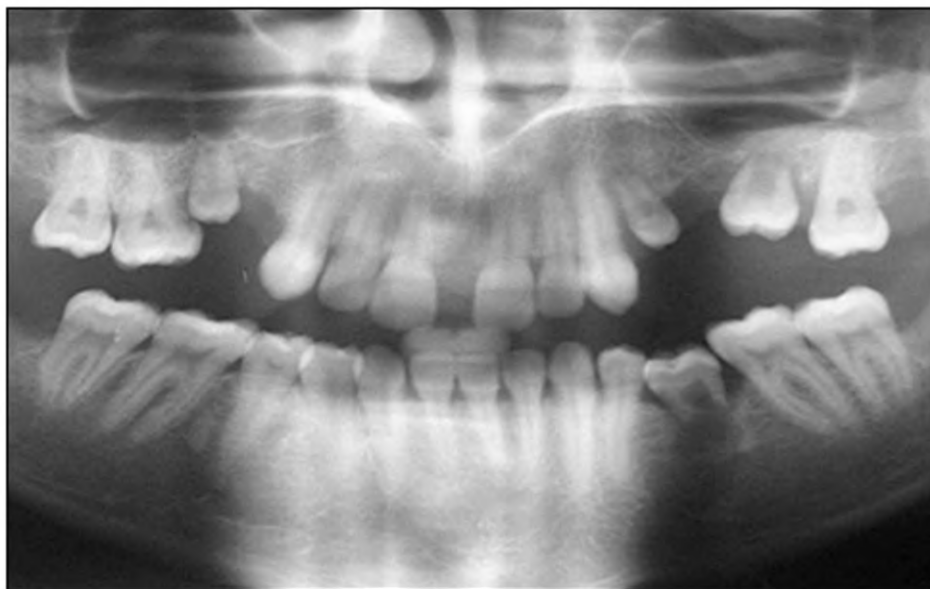
immature teeth. Occlusal surfaces of the crowns were left exposed, but all the teeth were splinted out of occlusion, with the help of figure eight sutures.

Amoxicillin 500 mg three times a day for five days was given to the patient prophylactically along with regular oral hygiene instructions.

An immediate postoperative panoramic radiograph showed the transplanted teeth in their new positions and the bone level around the immature roots (Figure 22). Three months

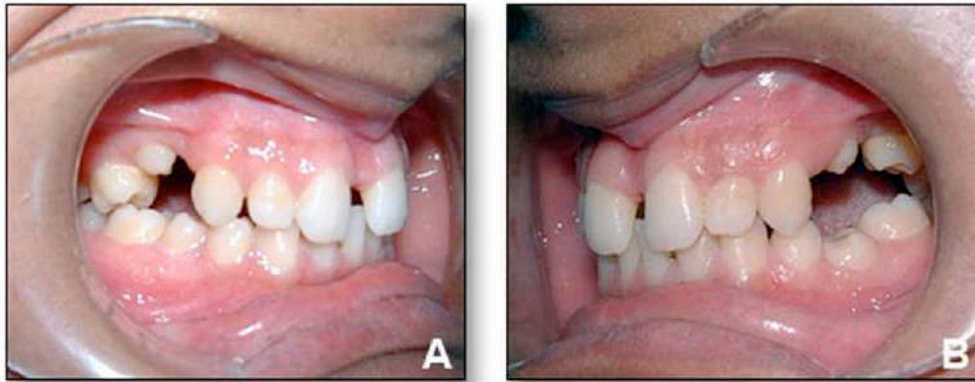


**Figure 21.** This radiograph was taken before extraction of the maxillary left first premolar by mistake.

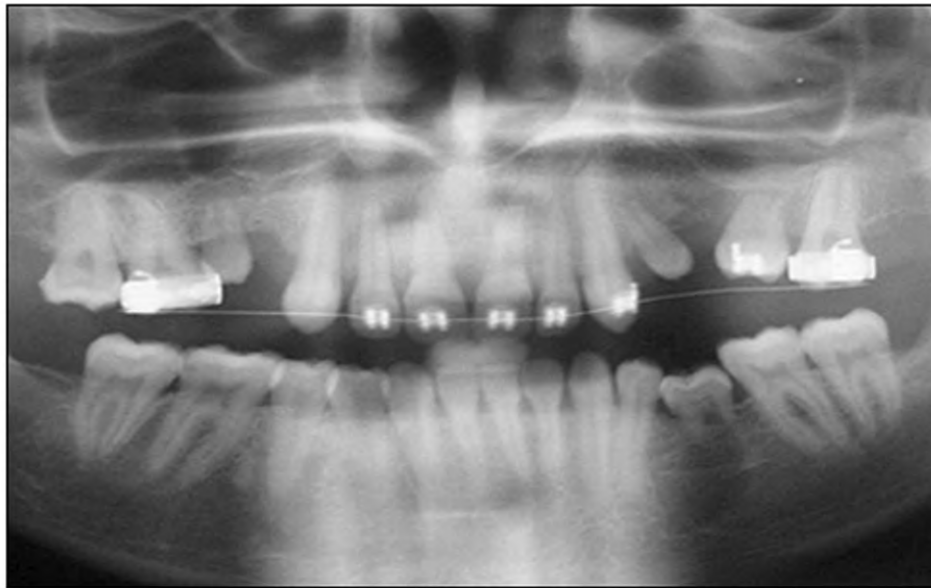


**Figure 22.** Immediate postoperative radiograph showed the compromised bone levels around autotransplanted teeth.





**Right and left views** three months after the procedure, showing the transplanted teeth in their new places.



**Figure 24.** Radiographs made nine months after surgery showing good new bone formation around the roots and minor eruption into occlusion.

later, very good healing was seen with good periodontal health and no significant pockets (Figure 23).

Nine months after the procedure, a new panoramic radiograph was made that showed good tooth eruption toward the occlusal plane accompanied with alveolar bone formation around the teeth (Figure 24). Autotransplantation benefits from the osteogenic activity of the immature transplanted teeth, contrary to dental implants, which would have required ridge augmentation in this case.

## Summary

As shown in these case reports, there are instances where the autotransplantation of teeth is appropriate and may possibly simplify future planned orthodontic or prosthodontic treatment. The bone formation around erupting teeth, due to the special osteogenic activity, is a major benefit of this treatment modality. Furthermore, for many patients, the economic considerations are critical, giving a priority to this treatment modality over dental implants or other prosthetic treatment.

In cases of missing teeth (mainly congenital), autotransplantation would be a very good treatment choice to be considered by dental practitioners.

## Clinical Significance

Tooth autotransplantation is an easy and good treatment option, applicable in a lot of cases, substituting for different types of prostheses, including dental implants.

## References

1. Guerini V. A history of dentistry from the most ancient times until the end of the eighteenth century. Philadelphia: Lea & Febiger; 1909, p. 191-2.
2. Clokie CM, Yau DM, Chano L. Autogenous tooth transplantation: an alternative to dental implant placement? J Can Dent Assoc. 2001; 67(2):92-6.
3. Reich PP. Autogenous transplantation of maxillary and mandibular molars. J Oral Maxillofac Surg. 2008; 66(11):2314-7.
4. Andreasen JO, Paulsen HU, Yu Z, Ahlquist R, Bayer T, Schwartz O. A long-term study of 370 autotransplanted premolars. Part I. Surgical procedures and standardized techniques for monitoring healing. Eur J Orthod. 1990; 12(1):3-13.
5. Moorrees CFA, Fanning EA, Hunt EE Jr. Age variation of formation stages for ten permanent teeth. J Dent Res. 1963; 42: 1490-502.
6. Kristerson L, Lagerström L. Autotransplantation of teeth in cases with agenesis or traumatic loss of maxillary incisors. Eur J Orthod. 1991; 13(6):486-92.
7. Jonsson T, Sigurdsson TJ. Autotransplantation of premolars to premolar sites. A long-term follow-up study of 40 consecutive patients. Am J Orthod Dentofacial Orthop. 2004; 125(6):668-75.
8. Andreasen JO, Paulsen HU, Yu Z, Bayer T, Schwartz O. A long-term study of 370 autotransplanted premolars. Part II. Tooth survival and pulp healing subsequent to transplantation. Eur J Orthod. 1990; 12(1): 14-24.
9. Kugelberg R, Tegsjö U, Malmgren O. Autotransplantation of 45 teeth to the upper incisor region in adolescents. Swed Dent J. 1994; 18(5):165-72.
10. Lundberg T, Isaksson S. A clinical follow-up study of 278 autotransplanted teeth. Br J Oral Maxillofac Surg. 1996; 34(2):181-5.
11. Cohen AS, Shen TC, Pogrel MA. Transplanting teeth successfully: autografts and allografts that work. J Am Dent Assoc. 1995; 126(4):481-5.
12. Nethander, G. Periodontal conditions of teeth autogenously transplanted by a two-stage technique. J Periodontal Res. 1994; 29(4):250-8.
13. Josefsson E, Brattström V, Tegsjö U, Valerius-Olsson H. Treatment of lower second premolar agenesis by autotransplantation: four-year evaluation of eighty patients. Acta Odontol Scand. 1999; 57(2):111-5.

## About the Authors

### Jawad A. Abu Tair, DMD



Dr. Abu Tair is an assistant professor of the Oral & Maxillofacial Surgery Department at the Arab American University at Jenin Dental School. He is a member of the Palestinian Dental Association with research interests in oral surgery.

e-mail: [djawadat@hotmail.com](mailto:djawadat@hotmail.com) or [jabutair@aauj.edu](mailto:jabutair@aauj.edu)

### Ahmad Rahhal, DDS, PhD



Dr. Rahhal is an assistant professor in the Department of Orthodontics at the Arab American University at Jenin Dental School. He is a member of the Palestinian Dental Association, the Arab Orthodontic Society, the European Orthodontic Society, and the WFO (World Federation of Orthodontics). His research interest is in functional orthopedic treatment, TMJ-TMD.

e-mail: [plorahhal@hotmail.com](mailto:plorahhal@hotmail.com) or [arahal@aauj.edu](mailto:arahal@aauj.edu)