

See discussions, stats, and author profiles for this publication at: <https://www.researchgate.net/publication/305495234>

Prevalence of Impacted and Transmigrated Canine among Palestinian People –Jenin District

Article · May 2016

CITATION

1

READS

65

1 author:



Ziyad Kamal Mohammad

Arab American University

12 PUBLICATIONS 3 CITATIONS

SEE PROFILE

Prevalence of Impacted and Transmigrated Canine among Palestinian People -Jenin District

Saleh I. Hijawi*, Ala'uddin M. Hussein, Ziyad K.M.Mohammad

Arab American University, Jenin, Palestine.

*corresponding author: hijawis@gmail.com

Received: 13-4-2016
Revised: 4 -5-2016
Published: 28-5-2016

Keywords:

*Canine,
Impaction,
Prevalence,
Transmigrated,
Retrospective*

Abstract: The purpose of this study was to investigate the incidence of impacted maxillary canines in a Palestinian population. The study consisted of a retrospective analysis of the panoramic records of 1683 patients. Statistical analysis was used to examine potential differences in the distribution of impacted maxillary and mandibular canines stratified by gender, location (left or right), unilateral and bilateral position, and presence of transmigration. It was found that the incidence of impacted canines was (2.9%). Of the 54 impacted canines, 30 were in females and 24 were in male patients. Ages were in the range of 16-47. Of these subjects, 38 (84.44%) had unilaterally impacted maxillary canines, while 7 (15.55%) had bilateral impactions. One case of transmigrated canine was recorded among the whole sample. As has been noted the incidence of impacted canines in the sample Palestinian population was (2.9%) which is comparable to the findings from previous studies.

Cite this article as: Hijawi, S.I., Hussein, A.M. and Mohammad, Z.K.M. (2016) Prevalence of Impacted and Transmigrated Canine among Palestinian People -Jenin District. *Journal of basic and applied Research* 2(3): 272-276
Like us on Facebook – [click here](#) Join us on academia – [click here](#) Be co-author with JBAAR on Google Scholar – [click here](#)

INTRODUCTION:

Dentists almost daily diagnose teeth that fails to line up into its own place. Impacted tooth do not erupt within the specific time blocked by gum, bone, or another tooth (Msagati et al., 2013). Some of them partially seen in the dental arch termed as Partially Impacted, while the Completely or Fully Impacted were buried and completely covered by bone and mucosa. Maxillary canines are the most commonly impacted teeth after the third molars (Figure 1) (Husain et al., 2012).

Obviously, Canines play an important role, in both aesthetics and function, in human dentition (Hijawi and Mohammad, 2015). The aetiology of canine impaction is associated with several systemic and local factors. These factors may include early loss of the deciduous canine or its prolonged retention, arch-length deficiency, supernumerary teeth, presence of pathological lesions in the region and ankylosis, dilacerated root, cleft lip and/or palate idiopathic condition with no apparent cause. Less common, systemic factors such as Cleidocranial dysplasia, Down syndrome, febrile diseases (Manne et al., 2012).

Third molar is the most frequently impacted tooth followed by maxillary canine, maxillary central incisors and premolars. The impaction prevalence was found to be disparate according to the population, and most studies have reported to be

between 6.9 and 76.6%. In particular, the incidence of canine impaction ranging from 0.8 – 3.6% of the general population (Aydin et al., 2004; Kamiloglu & Kelahmet, 2014). Migration of impacted tooth crossing the midline to the opposite side of the arch is termed as tooth transmigration (Sharma & Nagpal, 2014). (Figure 2) Uncommon phenomenon typically affects the mandibular canines. Tooth transmigration previously reported in the literature, studies found the prevalence of transmigration in the different populations ranging between 0.1% and 0.34% (Sharma & Nagpal, 2014). The etiology of transmigration is still unclear. In spite of this one of the theories stated that transmigration occurred when the tooth bud developed in abnormal site and alter eruption path (Sharma & Nagpal, 2014).

MATERIALS AND METHODS:

A retrospective study was conducted using panoramic radiographs of 1683 patients [719 (42.7%) males, 964 (57.3%) females] of age ranging from 16-47 years. All radiographs taken by the same radiologist technician between (September 2013 and February 2014). who is working in (Jenin Diagnostic X-Ray Center) a private center specialized in medical and dental radiography using digital panoramic machine (Kodak 9100, made in Germany) at 70 KVp, 10 mA for 14.3 seconds.

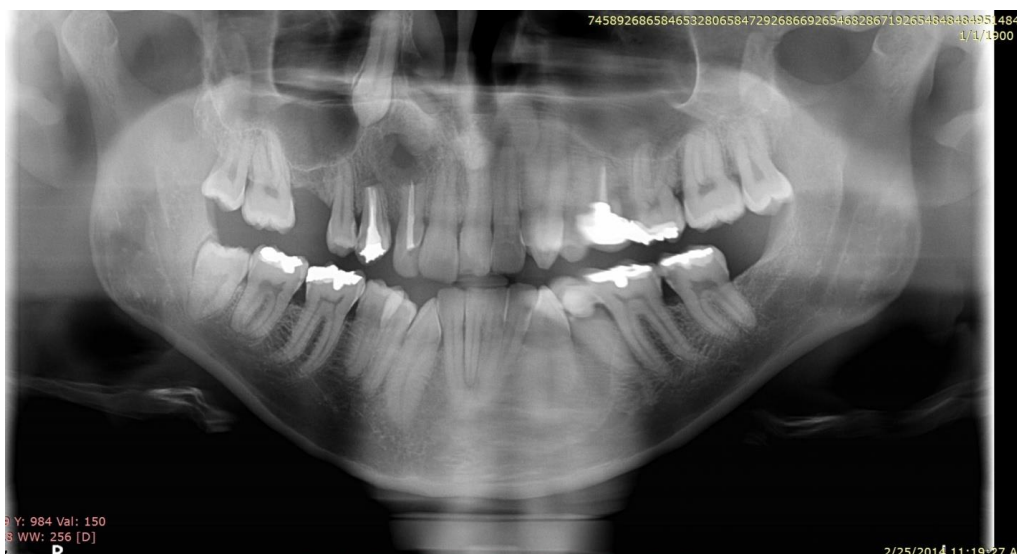

Figure 1: Panoramic X-ray showing upper right impacted canine

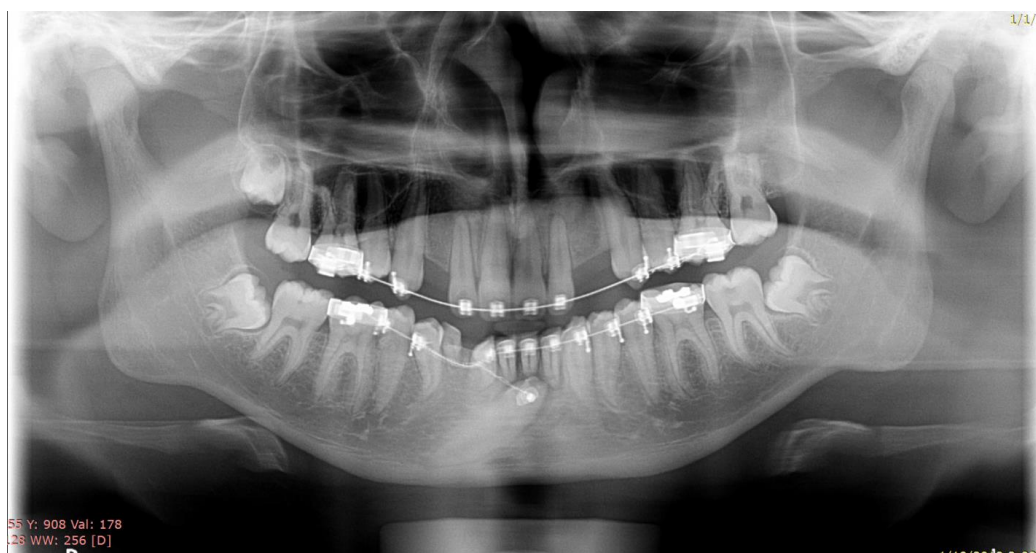

Figure 2: Panoramic radiograph showing transmigrated lower right canine below the apices of the anterior teeth.

One Oral & Maxillofacial Surgeon investigated all the subjects on the laptop screen using radiant DICOM viewer (version 1.9.16) to determine the frequency of canine impaction in each quadrant and observing canine transmigration. Any canine was not aligned with the rest of the teeth in occlusion was considered as impacted. Regarding transmigration considered when at least part of the tooth had crossed the midline. After that the whole readings were entered into data sheet of statistical package SPSS (version 14.0, software). Cases with underlying syndrome and Radiographs with poor-quality were excluded. Needless to say that the panoramic radiograph affords a perfect view of the whole oral structures, teeth and assists in detecting the ectopic tooth in the both jaws.

RESULTS:

Out of 45 panoramas that shows at least one impacted canine with impaction rate of 2.9%.

Seven presented with bilateral impaction, thirty eight showed unilateral impaction. In total of 54 canine impaction, distributed by arch 42 (77.8%) in maxilla and 12 (22.2%) in mandible. furthermore, classified according to sex 24 (44.4%) male and 30 (55.6%) female. Canine impaction in the left side was found to be more common 23 (59%) whereas the right side was 16 (41%). In other words, we defined unilateral impaction by the presence of only one canine tooth in any quadrant, and multiple impaction by the existence of at least two impactions either on ipsilateral or contralateral side. Noting that only one case out of 38 unilateral cases revealed ipsilateral multiple impactions on left side and the others showed only single impaction on any quadrant.

Among the bilateral cases, six of them was found in maxilla and one case in the mandible, observing that only one of the maxillary cases included multiple impaction, with extra lower left impacted

canine tooth. On the other hand, comparing the affected side with gender, the panoramas of the male patients showed 8 (38.1%) of the impacted canine on the right side. Whereas, the left side was 10 (47.6%) cases. Furthermore, 3 (14.3%) subjects were bilaterally affected. Regarding female patients impacted canine distributed to 8 (33.3%) on the right side, and 13 (54.2%) on the left. Moreover, 3 (12.5%) panoramas presented with bilateral canine impaction. Interestingly, only one case in our study showed impacted canine with transmigration (0.05%) in the lower right side of a male patient (Figure 2).

DISCUSSION:

Currently, Tooth impaction is a frequent incident in our dental office. therefore, many studies conducted on tooth impaction. Teeth show a wide range of prevalence of impaction, due to this the third molar displayed high frequency followed by maxillary canine. Considering canines play a very important role in functional occlusion, food tearing, and kind appearance on the corner of the mouth to contribute in aesthetic smile(Nagpal et al., 2009). The purpose of the present study is to assess the prevalence of the impacted canine.

Table 1: The distribution of unilateral impacted canine per quadrant





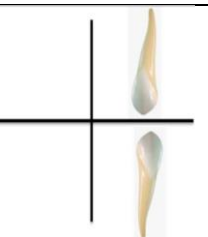
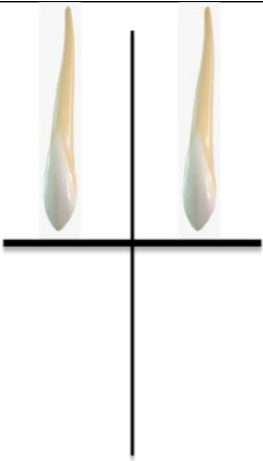
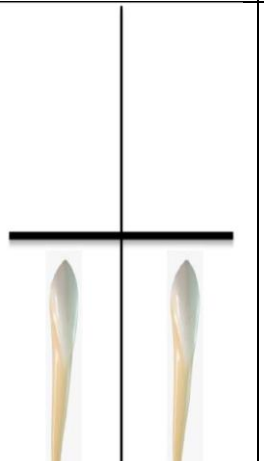
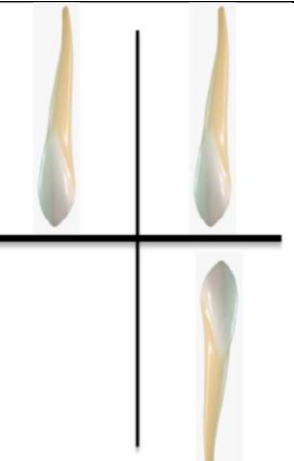
Upper right quadrant	Upper left quadrant	Lower right quadrant	Lower left quadrant	Multiple unilateral impaction
				
12 cases	17 cases	4 cases	4 cases	1 case

Table 2: The distribution of the bilateral impacted canine.

Upper Bilaterally	Lower Bilaterally	Multiple bilaterally impaction
		
5 Cases	1 Case	1 Case

To our knowledge there is no previous articles related to canine impaction in Palestine. In the current study, the overall prevalence of canine impaction is (2.9%) (Aydin et al., 2004).which is comparable with most ranges in previous studies. Out of 45 cases, the unilateral canine impaction is more common than the both sides. Thus, there are 38 cases with single impacted canine unilaterally which reported high occurrence 17 cases in the upper left quadrant followed by the upper right quadrant 12 cases. The lower arch presented with equal incidence of 8 impacted canines divided to 4 cases in each quadrant. (as shown in table 1).

In addition to that, one of the radiographs displayed ipsilateral canine impaction on the left side of the maxillary and mandibular arch. Meanwhile, canine impaction bilaterally was found in 7 conditions (as shown in table 2) . One of them was considered as multiple canine impaction case due to presence of another impacted canine in the lower left quadrant. Noting that most of bilateral cases was found in the maxilla 6:1 whereas only one case in the mandible. The majority of impacted canines located in the maxillary arch 42 (77.8%) whereas the mandibular arch presented with 12 (22.2%) (Stewart et al., 2001). which is in line with previously reported studies. In this study, Canine impaction showed incidence in female patients 30 (55.6%) more than males 24 (44.4%) with a ratio of 1.25:1 which is compatible with other studies (Gashi et al., 2014). As a result of higher frequency of dental anomalies among females in lateral incisor area and the smaller cranium in females (Gashi et al., 2014). Subsequently, the left side displayed high prevalence of impacted canine in the study population 23 (59%) while the right side 16 (41%). In detail, the left side is more affected than the right among males and females (Gashi et al., 2014). The incidence of the impacted canines in males on the right side 8 (38.1%) and the left side 10 (47.6%). However, the frequencies among females were 8 (33.3%) on the right and 13 (54.2%) on the left side. (as shown in table 3).

Table 3: Canine impaction prevalence on the right side and the left side among males and females.

Canine impaction in the right side		Canine impaction in the left side	
16 Cases (41%)		23 Cases (59%)	
Canine impaction in males		Canine impaction in females	
Right side	Left side	Right Side	Left side
8 Cases (38.1%)	10 Cases (47.6%)	8 Cases (33.3%)	13 Cases (54.2%)

Ultimately, another important observation in our study is the presence of one case of lower right transmigrated impacted canine among the 1683 radiographs. Inspected panoramic views with a prevalence of (0.05%) which is below the range of

previously reported studies. Notably that our results does not contain subjects with bilateral transmigration. The early detection of the impacted canines is essential in reducing complications and treatment time. Some of these complication root resorption of the lateral incisors, cystic lesions of the follicle and the need for more complex surgical and orthodontic intervention (Abron et al., 2004).

CONCLUSION:

The prevalence of impaction of permanent canine was found to be within the previously reported incidence. Our study may enrich the data base of the literature about canine impactions and transmigrations, which indeed influence the way of management of canine impactions.

REFERENCES:

Abron, A., Mendro, R. L., & Kaplan, S. (2004). Impacted permanent maxillary canines: diagnosis and treatment. *N Y State Dent J*, 70(9), 24-28.

Aydin, U., Yilmaz, H. H., & Yildirim, D. (2004). Incidence of canine impaction and transmigration in a patient population. *Dentomaxillofac Radiol*, 33(3), 164-169. doi:10.1259/dmfr/15470658

Gashi, A., Kamberi, B., Ademi-Abdyli, R., Perjuci, F., Sahat, #xe7, & iu-Gashi, A. (2014). The Incidence of Impacted Maxillary Canines in a Kosovar Population. *International Scholarly Research Notices*, 2014, 4. doi:10.1155/2014/370531

Hijawi S. I. and Mohammad, Z.K.M. (2015) Radiographic Assessment of the Incidence of Supernumerary teeth in a population of 1683 patients (Preliminary study). *Journal of basic and applied Research* 1(2): 48-54

Husain, J., Burden, D., McSherry, P., Morris, D., & Allen, M. (2012). National clinical guidelines for management of the palatally ectopic maxillary canine. *Br Dent J*, 213(4), 171-176.

Kamiloglu, B., & Kelahmet, U. (2014). Prevalence of impacted and transmigrated canine teeth in a Cypriote orthodontic population in the Northern Cyprus area. *BMC Research Notes*, 7(1), 1-6. doi:10.1186/1756-0500-7-346

Manne, R., Gandikota, C., Juvvadi, S. R., Rama, H. R., & Anche, S. (2012). Impacted canines: Etiology, diagnosis, and orthodontic management. *J Pharm Bioallied Sci*, 4(Suppl 2), S234-238. doi:10.4103/0975-7406.100216

Msagati, F., Simon, E., & Owibingire, S. (2013). Pattern of occurrence and treatment of impacted teeth at the Muhimbili National Hospital, Dar es Salaam, Tanzania. *BMC Oral Health*, 13(1), 1-6. doi:10.1186/1472-6831-13-37

- Nagpal, A., Pai, K. M., Setty, S., & Sharma, G. (2009). Localization of impacted maxillary canines using panoramic radiography. *J Oral Sci*, 51(1), 37-45.
- Sharma, G., & Nagpal, A. (2014). A Study of Transmigrated Canine in an Indian Population. *International Scholarly Research Notices*, 2014, 9. doi:10.1155/2014/756516
- Stewart, J. A., Heo, G., Glover, K. E., Williamson, P. C., Lam, E. W., & Major, P. W. (2001). Factors that relate to treatment duration for patients with palatally impacted maxillary canines. *Am J Orthod Dentofacial Orthop*, 119(3), 216-225.