

ORTHO TRIBUNE

The World's Orthodontic Newspaper • Middle East & Africa Edition

PUBLISHED IN DUBAI

www.dental-tribune.me

May-June 2017 | No. 3, Vol. 7

Orthodontic Extrusion of Traumatically Intruded Upper Central Incisor

By Prof. Emad Hussein, Jordan, Asst. Prof. Mohammed Jaradat, Jordan, Assoc. Prof. Alev Aksoy, Jordan, Dr. Fadi Khuffash, Palestine, Prof. Ahmad Hamdan, Jordan

Introduction

The incidence of traumatic dental injuries varies with age and has a high prevalence worldwide. [1] In most cases, the front teeth are the most affected, with the central incisors being at the highest risk of dental trauma. [2] [3] The maxillary arch is involved in a higher percentage (95.72%) of incidents when compared to the mandibular arch. [4]

Intrusion luxation can be defined as the form of traumatic dental injury that leads to tooth displacement deep into the alveolar bone. This usually results in severe complications (pulp necrosis, inflammatory root resorption, ankylosis); for this reason it is classified as a severe form of traumatic dental injury. [5] [6]

Management of traumatically intruded anterior teeth is of prime importance, since these teeth are so important both aesthetically and functionally. Management of these traumatised teeth differs according to the root apex maturity and the severity of the intrusion luxation itself. Pulp necrosis occurs in one hundred percent of cases involving intrusion luxation of mature permanent teeth with fully-formed apex and in 62.5% of those involving intruded teeth with open apex. [7] [8] This case report aims to emphasise the importance of immediate orthodontic

loading of traumatically intruded mature permanent teeth with closed root apex.

Diagnosis and Etiology

A 15-year-old female was referred to the orthodontic clinic for dental evaluation. Her chief complaint was, "I have a displaced upper front tooth following a sport accident." (Figure 1) During orthodontic evaluation, the patient reported that she had received a sport injury one day ago. As an emergency treatment, she received immediate therapy by a general dentist, consisting of bleeding control, prescription of an antibiotic and an anti-inflammatory analgesic. Clinically, "The patient presented a dolichofacial pattern and normal occlusion, with well-aligned teeth, except for the traumatised upper left central incisor (4 mm intrusion depth) (Figures 1 and 2). Symptoms of temporomandibular disorders were not found. Pulp vitality of the traumatised tooth was tested with ethyl chloride, and a negative result indicated the presence of necrotic pulp tissue."

Treatment Objectives

The patient had an intruded upper left central incisor tooth as a result of a traumatic accident, so the following treatment objectives were established:

1. Extrude the intruded upper left central incisor into its original physiologic position
2. Allow easy access for necrotic pulp extirpation from the intruded incisor.

Treatment Plan

The treatment plan should aim to extrude the intruded tooth back into its original physiologic position within the upper arch. Three treatment alternatives were available:

1. Giving the tooth its own chance to re-erupt spontaneously.
2. Surgical repositioning for the intruded tooth
3. Orthodontic extrusion.

The authors preferred the third treatment option, so the treatment plan was to orthodontically extrude the traumatically intruded upper left central incisor as soon as possible following the traumatic injury.

Additionally, endodontic treatment was also planned in order to extirpate the necrotic pulp (the tooth had complete root development), thus minimising the chances of external root resorption and tooth loss.

Treatment Progress

Two days after the traumatic injury, the authors were able to bond the upper teeth with a fixed orthodontic appliance extending from the upper right 1st permanent molar to the upper left 1st permanent molar. A 0.022-in slot / Roth prescription pre-adjusted brackets (Pinnacle-Ortho Technology) were used with a 0.012 inch NiTi orthodontic wire (Ortho

Technology company) as an initial aligning arch wire. (Figure 3)

During the first week of treatment, the patient was instructed to follow a soft diet, with the aim of avoiding any traumatic contact with the traumatised tooth.

Three weeks following the start of the alignment phase, the tooth was extruded enough (close to the level of the other central incisor) to allow easy access for necrotic pulp extirpation (ethyl chloride examination confirmed the necrotic pulp status).

Page E2

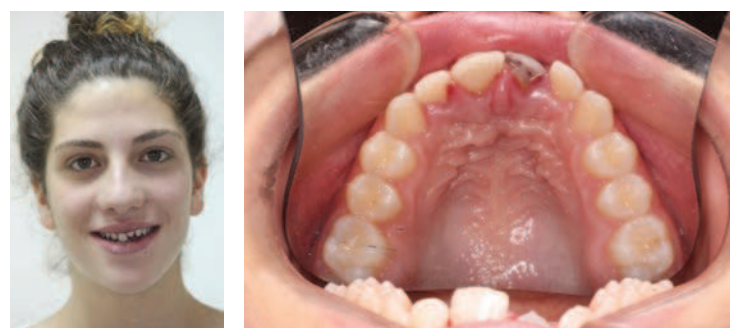

Figure 1

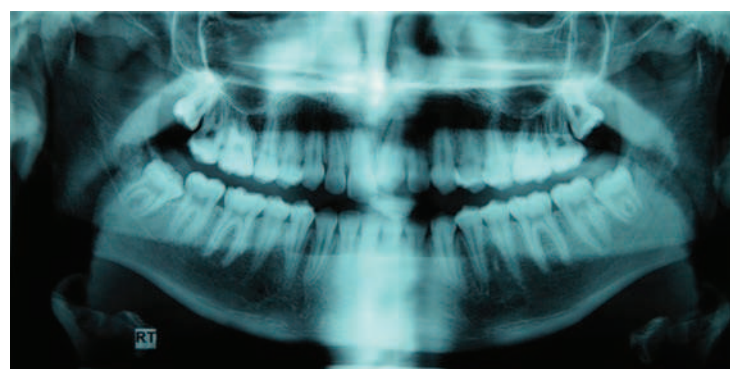


Figure 2

ORTHO SPECIALISTS

Positioner

First Class

Fast Track

Sleep Apnea

Quad Helix

www.qualident-online.com

Follow us on:

QUALIDENT
DENTAL LABORATORY

Tel. No. +971 4 342 7576
Fax: +971 4 342 7016
Email: info@qualident-online.com

◀Page E1

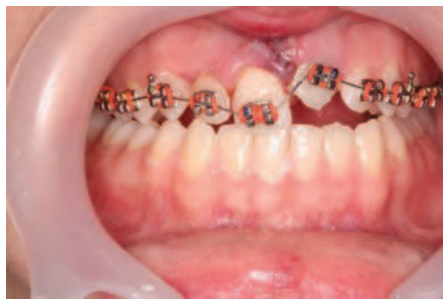

Figure 3

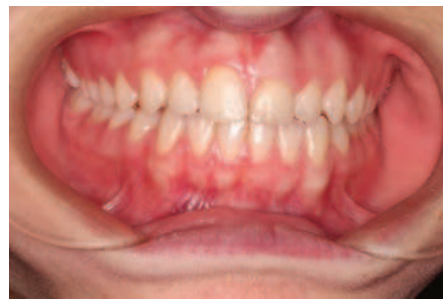

Figure 4a

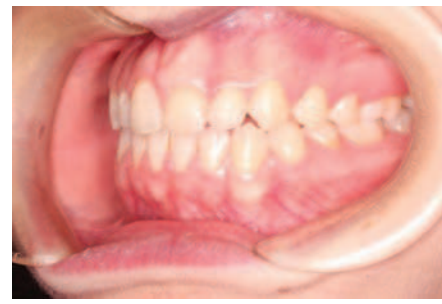

Figure 4b

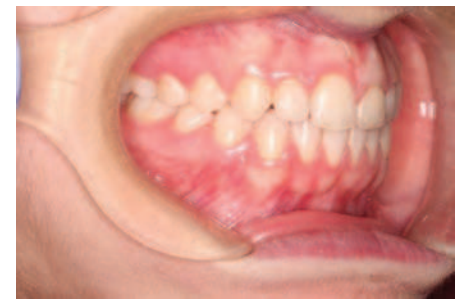

Figure 4c



Figure 4d

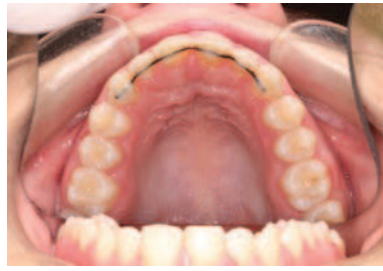

Figure 5

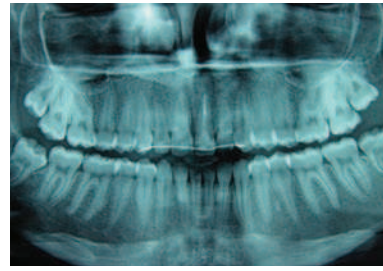


Figure 6

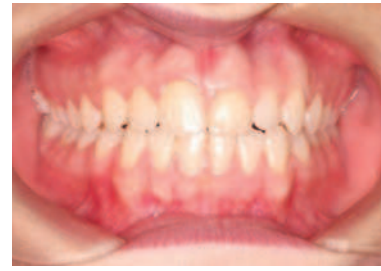

Figure 7

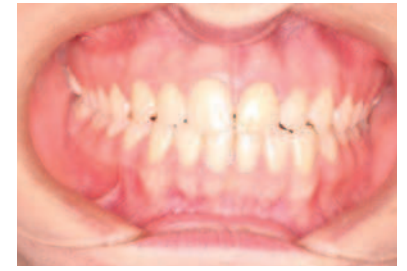

Figure 8

(Figure 3) The necrotic pulp was extirpated two weeks following the start of orthodontic treatment and a non-setting calcium hydroxide root canal filling material was placed for about three weeks. The aim of using the calcium hydroxide dressing material was to dissolve any pulp remnants, and to alkalise the environment to minimise the inflammatory root resorption. [9]

Then 0.014 and 0.016 inch NiTi wires (Ortho Technology Company) were used, in order to complete the alignment phase by moving the traumatised tooth back into its normal and physiological position. The alignment phase took about three months, after which the tooth was

normally positioned within the line of the arch. (Figure 4: a-d)

The result was maintained with an upper fixed lingual retainer (Ortho Technology) extending from upper right canine to upper left canine. (Figure 5, 6)

By the end of treatment, the gingival margin of the affected tooth was not level with the contralateral central incisor (Figure 4:A); this may be the result of the rapid extrusive forces which were applied to the intruded tooth. A gingivectomy for the upper left central incisor was performed about one year later in order to level it with the gingival margin of the right central incisor. (Figure 7,8)

Discussion

Traumatic intrusion luxation is a serious type of injury, and it occurs most frequently in upper incisors. [4] Management of traumatically intruded permanent teeth differs according to the root apex maturity and the severity of the luxation injury itself. In case of mild intrusion of teeth with incomplete root formation, the intruded teeth are given the chance to re-erupt spontaneously within three weeks. [10] [11] [12] If the intruded tooth does not erupt by itself during the three week observation period, it is preferable to extrude the tooth, in order to replace it in the line of the arch.

In our case, spontaneous re-eruption was not preferred because, accord-

ing to the UK national clinical guidelines, the chances of spontaneous re-eruption in mature teeth are low, especially if the intrusion is above 3 mm and, if eruption occurs, the tooth will not reach up to the pre-injury occlusal level. [12] [13]

As a result, the authors preferred immediate orthodontic extrusion, aiming to minimise the chance of ankylosis. This concurs with Andreasen, who states that orthodontic forces should be applied within the first few days following the intrusive luxation injury. [14] The initial arch wire was thin with low force to minimise any heavy and non-physiologic loading on the luxated tooth).

Endodontic treatment was mandatory in our case, since the intruded tooth had a fully-formed root with completely closed apex. [7] The pulp was extirpated, to avoid the development of external root resorption, which can lead to tooth loss. [15] Surgical repositioning was not preferred because it usually produces severe trauma to the periodontal ligament, leading to replacement resorption and tooth loss. [16]

Conclusion

The application of immediate orthodontic extrusive forces to reposition the traumatically intruded upper left permanent central incisor was effective. Early tooth repositioning created easy access for pulp extirpation which probably minimised the chances of external root resorption, ankylosis and hence tooth loss.

Acknowledgements

We have to thank Dr Majd Salameh for performing the endodontic treatment of the traumatically intruded upper central incisor

References

1. Kaste LM, Gift HC, Bhat M, Swango PA Prevalence of incisor trauma in persons 6-50 years of age United States: J Dent Res. 1996; 75 Spec No: 696-705 1988-1991
2. Ellis RG, Davey KW The classification and treatment of injuries to the teeth of children. 5th Edn Chicago: Year book publishers Inc 1970
3. Andreasen JO Etiology and pathogenesis of traumatic dental injuries. A Clinical Study of 1298 Cases Stand J Dent Res 78:339-42 1970
4. Saroglu I, Soñmez H The prevalence of traumatic injuries treated in the pedodontic clinic of Ankara University, Turkey, during 18 months Dent Traumatol. 18:299-303 2002
5. Andreasen JO Luxation of permanent teeth due to trauma Stand J Dent Res 78: 273-286 1970
6. Wigen TI, Agnalt R, and Jacobsen I Intrusive luxation of permanent incisors in Norwegians aged 6-17 years:

a retrospective study of treatment and outcome Dental Traumatology, vol. 24, no. 6, pp. 612-618, 2008

7. Andreasen FM, Pedersen BV Prognosis of luxated permanent teeth development of pulp necrosis Endod Dent Traumatol 1:207-20 1985)

8. Andreasen FM Pulpal healing after luxation injuries and root fracture in the permanent dentition Endodontics & Dental Traumatology, vol. 5, no. 3, pp. 111-131, 1989

9. Siqueira Jr. JF and Lopes HP Endodontia—Biologia e Técnica 3rd edition, Rio de Janeiro, Brazil: Guanabara Koogan 2004

10. Bruszt P Secondary eruption of teeth intruded into the maxilla by blow Oral Surg Oral Med Pathol. 11:146-9 1958

11. Ravin Intrusion of permanent incisive Tandlaeget 79:643-6. 1975

12. Turley PK, Joiner MW, Hellstrom S The effect of orthodontic extrusion on traumatically intruded teeth. Am J Orthod Dentofacial Orthop. 85:47-56 1984

13. Vahid Golpayegani M, Tadayon N A multidisciplinary approach to the treatment of traumatically intruded immature incisors. A 6-year follow up Iran: Endod J. Winter; 1(4):151-5 2006 Epub 2007 Jan 20

14. Andreasen JO Traumatic injuries of the teeth Philadelphia: W.B. Saunders Company 1981

15. Oulis C, Vadiakas G, and Siskos G Management of intrusive luxation injuries, Endodontics and Dental Traumatology, vol. 12, no. 3, pp. 113-119, 1996

16. Epker BN, Pandus PJ Root resorption activity after replantation of mature permanent incisors in monkeys Swed Dent J 4: 101-1 10, 1980 Surgical-orthodontic correction

Emad Hussein

Professor, Department of Orthodontics, Arab American University, Palestine

Mohammed Jaradat

Assistant Professor, Department of Orthodontics, Arab American University, Palestine

Alev Aksoy

Associate Professor, Süleyman Demirel University, Department of Orthodontics, Isparta, Turkey

Ahmad Hamdan

Professor, Department of Orthodontics, University of Jordan, Amman, Jordan

Fadi Khuffash

Master in Aesthetic Dentistry, Private practice, Ramallah, Palestine

inspire
Ice™

NOW AVAILABLE in all popular prescriptions, including the **MCLAUGHLIN, BENNETT, TREVISI* RX!**

To learn more, visit ormco.eu, call **800-854-1741**, or speak with your Ormco representative.

© 2017 Ormco Corporation *Does not imply endorsement

Ormco
Your Practice. Our Priority.

A Practical Treatment Objective: Alveolar Bone Modeling with a Fixed, Continuous-Arch Appliance




Figure 1. Alveolar Process

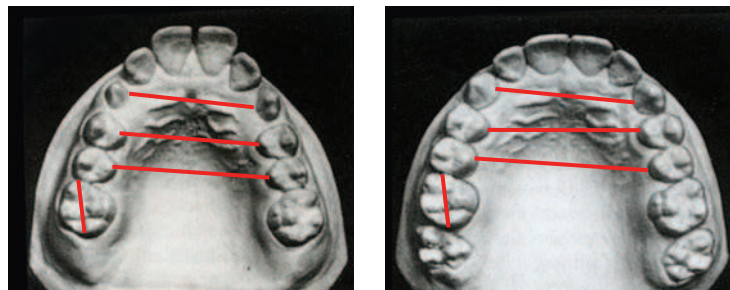


Figure 2. Typical transverse alveolar modeling observed in response to treatment with the Frankel Function Regulator. Pretreatment study model shown on the left and post-treatment on the right, size-corrected and marked for transverse development.

By Thomas W. Barron & Frank Bogdan, USA

Bone is a dynamic tissue that is continuously adapting its structure via the processes of remodeling and modeling. Remodeling is the coupled sequence of resorption and formation involved in physiologic turnover. It is necessary to adjust internal architecture in response to mechanical needs, repair microdamages in the bone matrix, and to maintain plasma calcium homeostasis. Remodeling can only be observed histologically or by chemical assay of biomarkers. Modeling is a change in the size and shape of a bone that can be observed and measured radiographically. It is the net gross anatomic result of bone resorption and formation on a given bone surface in response to growth and development or mechanical load. These processes are well-accepted phenomena in the field of physiology.

In the orthodontic literature, it is widely held that the alveolar bones of the maxilla and mandible are immutable—that once formed, their size and shape cannot be changed significantly with tooth-borne, continuous-arch orthodontic appliances. Attempts to do so have been associated with root and cortical plate resorption, loss of periodontal attachment and unstable tipping of teeth.¹⁻⁴ Under this paradigm, orthodontic treatment must maintain the existing size and shape of the alveolar bone. In many cases, this can only be accomplished with surgery, tooth extraction, or separation of the midpalatal suture.

In recent years, there has been a growing body of clinical evidence bolstered by studies that challenge the immutability of the alveolar bone and the mandate to treat to the existing dentoalveolar arch form.

The purpose of this article is to present a review of the literature challenging alveolar bone immutability along with clinical cases treated with passive self-ligating orthodontic brackets and low-friction/low-force protocols that demonstrate alveolar bone modeling.

Challenging Alveolar Bone Immutability

The alveolar process is defined as that part of the maxilla and mandible that forms and supports the sockets of the teeth (Fig. 1).

It includes the thin lamella of bone that surrounds the root of the tooth and gives attachment to the principal fibers of the periodontal ligament.

It also includes the supporting inner and outer cortical plates of compact bone along with the spongy bone between the cortical plates.⁵ Though anatomically, no distinct boundary exists between the body of the maxilla or the mandible and their respective alveolar processes, the bone surrounding the teeth from root apex to the crest of the socket is considered to be the alveolar bone.⁶

By means of the teeth, alveolar bone can be loaded with biomechanical force. The cellular response of the PDL to orthodontic force has been well characterized on both the pressure and tension sides of the bony socket surrounding the root as the tooth and its periodontal ligament are translated through the trough of bone confined by the buccal and lingual cortical plates.⁷⁻¹⁰ Until recently, modeling—or changing the size and shape of the developed alveolus by translating the cortical plate—was not deemed possible with fixed orthodontic appliances, and consequently, has not undergone rigorous study. The critical questions that must be answered to challenge alveolar bone immutability and foster an acceptance of treatment modalities that are not confined to the existing size and shape of the alveolus are:

1. Is the alveolus, confined by the buccal and lingual cortical plates, immutable or is there evidence that it can undergo modeling?
2. If it can undergo modeling, under what conditions can it occur?
3. Can fixed, continuous-arch orthodontic appliances induce alveolar bone modeling?
4. Is there a cellular mechanism of action that can explain orthodontic-induced alveolar bone modeling?

Myo-Periosteal Induction of Alveolar Bone Modeling

Dr. Rolf Frankel described the transverse alveolar modeling observed in periadolescent patients treated with his Function Regulator Appliance (Fig. 2).¹¹⁻¹³ He reported that the increase in the transverse dimension observed in these patients is achieved primarily through the action of the buccal shields on the appliance. The acrylic shields disrupt the equilibrium of forces acting on the dentoalveolus by removing the

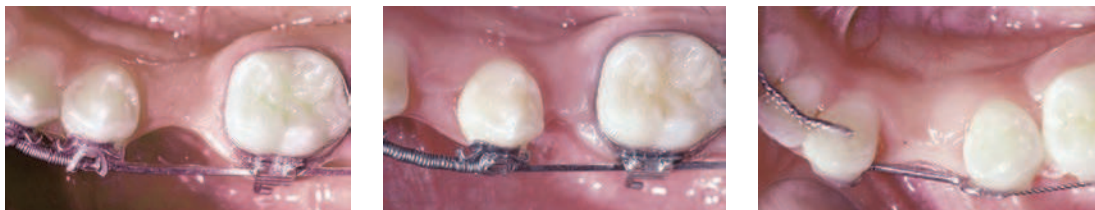

Figure 3. From Kokich, G., Kokich, V.: Congenitally missing mandibular second premolars: clinical options Am. J. Orthod. 130:437, 2006.

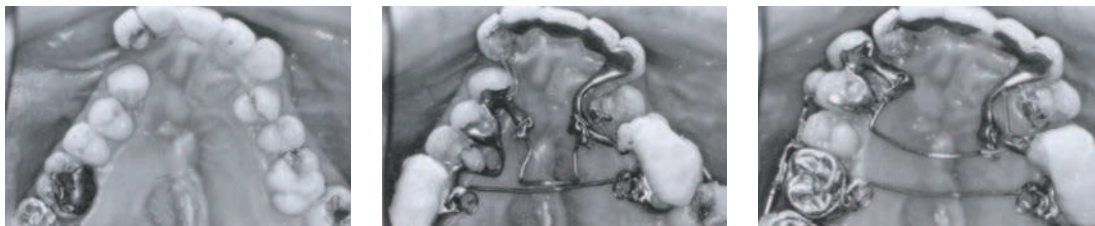

Figure 4. Alveolar bone modeling with the low load, constant force Passive/Active Dissociation Appliance described by Fontenelle. From Fontenelle, A: Challenging The Boundaries of Orthodontic Tooth Movement in Orthodontics for the Next Millennium, ed., R. Sachdeva, H.P. Bantleon, L. White, J. Johnson, ORMCO Glendora 1997, pp. 248-267

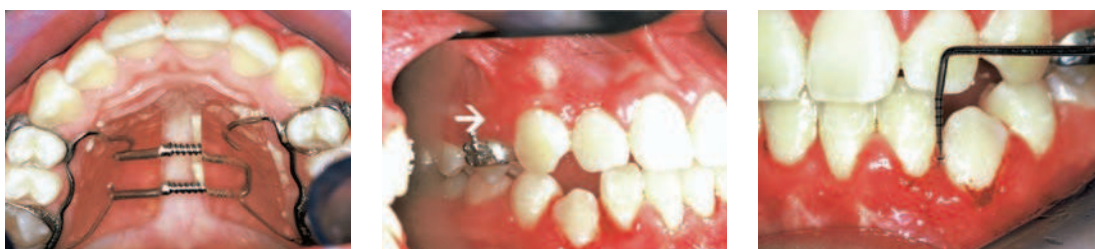

Figure 5a-c. From Williams, M.O., Murphy, N.C.: Beyond the ligament: a whole bone periodontal view of dentofacial orthopedics and falsification of universal alveolar immutability, Semin Orthod 14:246, 2008.

pressure of the buccal musculature and allowing the light continuous force of the tongue to dominate. According to Frankel, when the forces of the cheeks are eliminated, the teeth tip laterally in the direction of least resistance. The alveolar walls in the radicular area are likewise deformed in a buccal direction.

Furthermore, the acrylic shields extending into the vestibule exert a constant outward pull on the connective tissue fibers and muscle attachments that is transmitted to the alveolar bone by the fibers of the periosteum. Apposition of buccal bone aids in the lateral movement of the dentoalveolus. The ability of periosteal tension to induce apposition of bone on the lateral alveolus has been demonstrated in the animal studies of Altmann¹⁴⁻¹⁶ and Harvold.^{17,18} In addition, a study by Breiden, et al.,¹⁹ utilizing metallic implants placed in the maxillae of patients treated with the Frankel appliance demonstrated that widening of the maxilla was due to deposition of new bone along the lateral border of the alveolus rather than increased growth at the midpalatal suture.

This phenomenon of alveolar modeling, specifically lateral translation of the alveolus, achieved by disrupting the equilibrium of the inner and outer oral musculature and periosteal tension is consistent with the Functional Matrix Theory of Moss.²⁰⁻²² While granting the innate growth potential of cartilage and bone, his theory holds that growth of the face occurs as a response to functional needs and neuromuscular influences and is mediated by the soft tissue in which the jaws are embedded. The theory, simply stated, is that bones do not grow but are grown, emphasizing the ontogenetic primacy of function over form. The Frankel appliance achieves a change

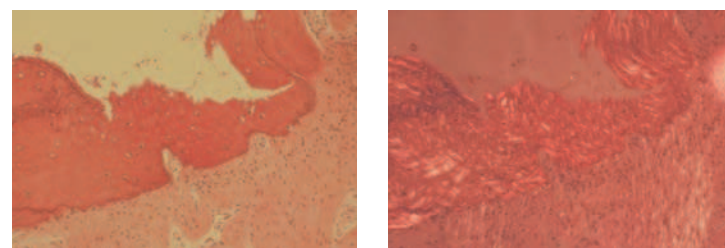


Figure 6a-b. Routine hematoxylin and eosin histological section at buccal aspect of tooth #5, labial to Max 2000 palatal alveolus development appliance. Note absence of a "lamellar" pattern that is characteristic of mature bone (a). A polarized light section of specimen. Note "woven bone" pattern characteristic of immature bone (b). From Williams, M.O., Murphy, N.C.: Beyond the ligament: a whole bone periodontal view of dentofacial orthopedics and falsification of universal alveolar immutability, Semin. Orthod. 14:246, 2008.

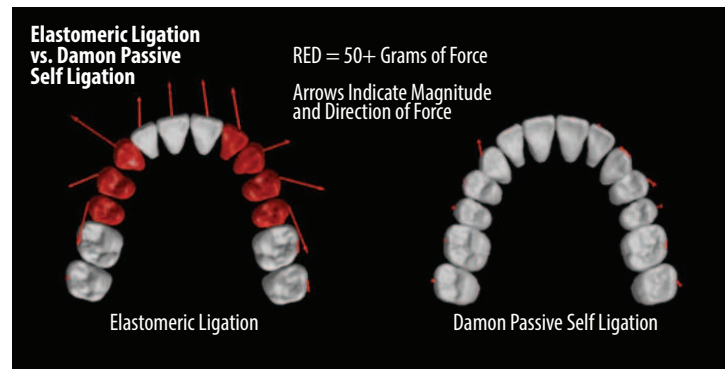


Figure 7. A malocclusion simulating bilaterally high canines leveled and aligned on an .014" Copper Ni-Ti wire with elastomeric ligation and Damon passive self ligation. Elastomeric ligation demonstrated labial force vectors with higher forces compared with Damon passive self-ligation appliances. Data reprinted by permission from Dr. Hisham Badawi.

in form by changing the function of the matrix tissues of the orofacial musculature.

Load-Induced Alveolar Bone Modeling

It is commonly observed in the field of dental medicine that the continuous load of a growing odontogenic cyst can significantly model the alveolar bone of the maxilla and mandible, causing remarkable displacement of the cortical bone.²³ This pathologic process is well established

and has been extensively documented in case reports and textbooks. The interstitial pressure of various odontogenic cysts have been measured²⁴ and found to exert an ultra-low force load on the alveolar bone. This phenomenon clearly demonstrates that the developed alveolus can be modeled via pathologic induction with light, continuous force. Another commonly observed example of

◀Page E3

bone modeling is the bulge of the cortical plate associated with a palatally impacted canine. The impacted tooth is typically associated with an enlarged follicle. When the canine is exposed and brought into the center of the alveolus, a normal palatal contour returns.

Kokich and Kokich²⁵ demonstrated localized modeling of the adult alveolus in response to tooth displacement. Light, continuous orthodontic force was employed to distalize a tooth into the atrophic alveolar ridge associated with a congenitally absent second premolar. The distalized tooth moved with its supporting bone, changing the size and shape of the atrophic alveolus (Fig. 3).

Fontenelle reported alveolar bone modeling with a passive/active dissociation appliance in non-growing patients.²⁶ The appliance (Fig. 4) consisted of a passive, rigid-cast lingual arch and active, low-modulus wires

activated between the cast lingual arches. Dissociation of the passive and active components facilitates the application of low, constant force load with near-constant moment-to-force ratios, resulting in bone modeling induced by dental displacement. Clinical cases were shown demonstrating lateral modeling of the alveolus as observed by Frankel and localized alveolar modeling with tooth displacement as observed by Kokich and Kokich.

Williams and Murphy described alveolar bone modeling with evidence of apposition of bone on the maxillary buccal alveolus in permanent dentition patients (Fig. 5a-c).²⁷ This was induced by a light, continuous load applied bilaterally to the maxillary alveolus with the Max 2000[®] alveolar development appliance (Fig. 5a).^{*} Their appliance consists of two nickel-titanium springs embedded in and connecting separate acrylic panels in a framework retained by

bands on the first bicuspid and first molars. The transpalatal springs delivered 150 grams of force each in a lateral direction. Biopsies were performed on two patients upon completion of lateral alveolar development. The specimens were harvested via full-thickness flaps from the labial alveolar crest between the maxillary right first bicuspid and canine (Fig. 5b). An internal control specimen was taken from interseptal bone between the ipsilateral mandibular first bicuspid and canine (Fig. 5c). Standard hematoxylin and eosin stained sections were examined with and without polarized light and a maxillary specimen was subjected to fractional analysis.

The maxillary treatment sections demonstrated the absence of the lamellar pattern characteristic of mature bone and polarized light demonstrated a woven bone pattern characteristic of immature or new bone (Fig. 6). In addition, fractional

analysis of the polarized light specimen demonstrated fractal patterns suggestive of woven bone modeling.

Alveolar Bone Modeling with a Fixed, Continuous-Arch Appliance

In recent years, fixed, passive self-ligating (PSL) appliances have been developed along with low-friction/low-force, continuous-arch protocols for orthodontic treatment. Dr. Hisham Badawi has reported evidence²⁸ with his OSIM apparatus²⁹ supporting the ability of passive self-ligating brackets to deliver lower-magnitude forces compared with elastomeric-ligated appliances applied to the same malocclusion in an in vitro model (Fig. 7). Evidence has also been reported supporting the ability of passive self-ligating brackets to achieve a reduction in the frictional resistance to sliding at the bracket/wire interface.^{30,31,32} The resultant load applied to the teeth

and transmitted to the alveolar bone necessarily decreases as the frictional resistance to sliding and the force required to overcome it decreases. Clinical evidence has been reported demonstrating significant widening of the dental arches following treatment with the low-friction/low-force Damon System.^{33,34,35} An increase in the transverse dimension of the alveolar bone has also been reported in response to the low, biomechanical load delivered by this treatment regimen.^{36,37}

The following case reports provide examples of the alveolar bone modeling the authors have observed over a combined 28 years of experience utilizing the Damon passive self-ligating fixed appliance and treatment protocols advocated by Dr. Dwight Damon.

**CASE STUDY 1
CHILD ALVEOLAR MODELING:
Pretreatment**

Diagnosis

A 9-year-old male patient presented in the mixed dentition with premature loss of his maxillary left primary canine with space loss and a blocked-out, unerupted permanent canine. His mandibular arch presented with severe crowding and completely blocked-out and unerupted lateral incisors. He exhibited normal circumoral muscle tonus and lip competence. The lateral ceph showed upright maxillary and mandibular incisors.

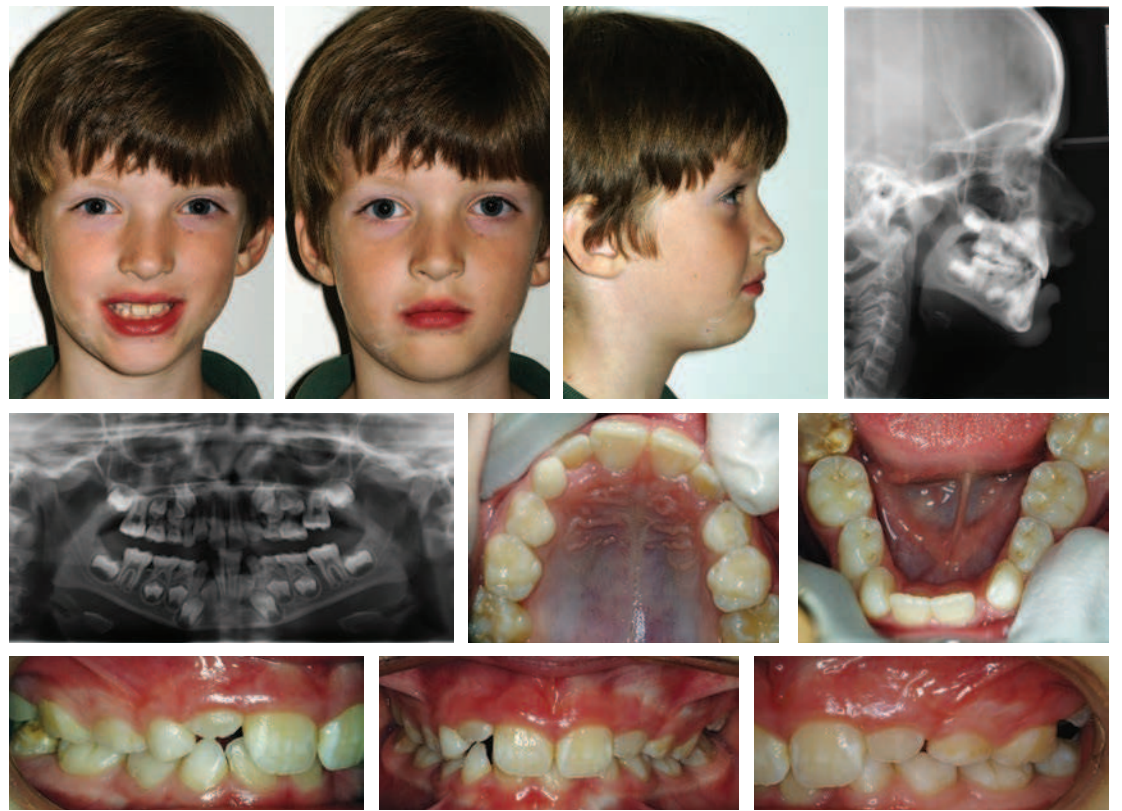
Treatment Summary

Phase I mixed-dentition treatment was initiated with Damon passive self-ligating appliances, including brackets placed on all the non-mobile primary teeth. Copper Ni-Ti wires (.014") and light NiTi coil

springs were activated one-half-of-a-bracket length between the mandibular permanent central incisors and primary canines, and between the maxillary left permanent lateral incisor and primary first molar. Low-torque brackets were selected for the upper and lower incisors to help minimize proclination from the force of the spring. Damon wire sequence protocols were observed.

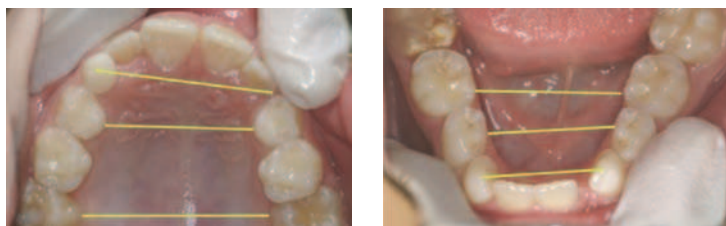
Result

Pre- and posttreatment images demonstrate the treatment result after 16 months of treatment. The size-corrected view of the mandibular arch illustrates the significant change in the size and shape of the mandibular alveolar bone induced by this approach. Similar changes were seen in the maxilla as well. The patient's parents were pleased with the result of Phase I treatment and opted not to pursue Phase II finishing treatment.

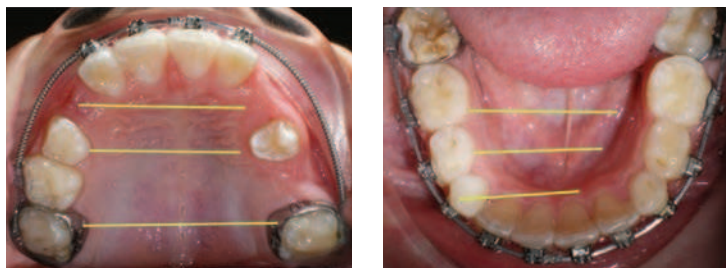


**CHILD ALVEOLAR MODELING:
Pre-/Posttreatment Comparison Demonstrates Alveolar Bone Modeling**

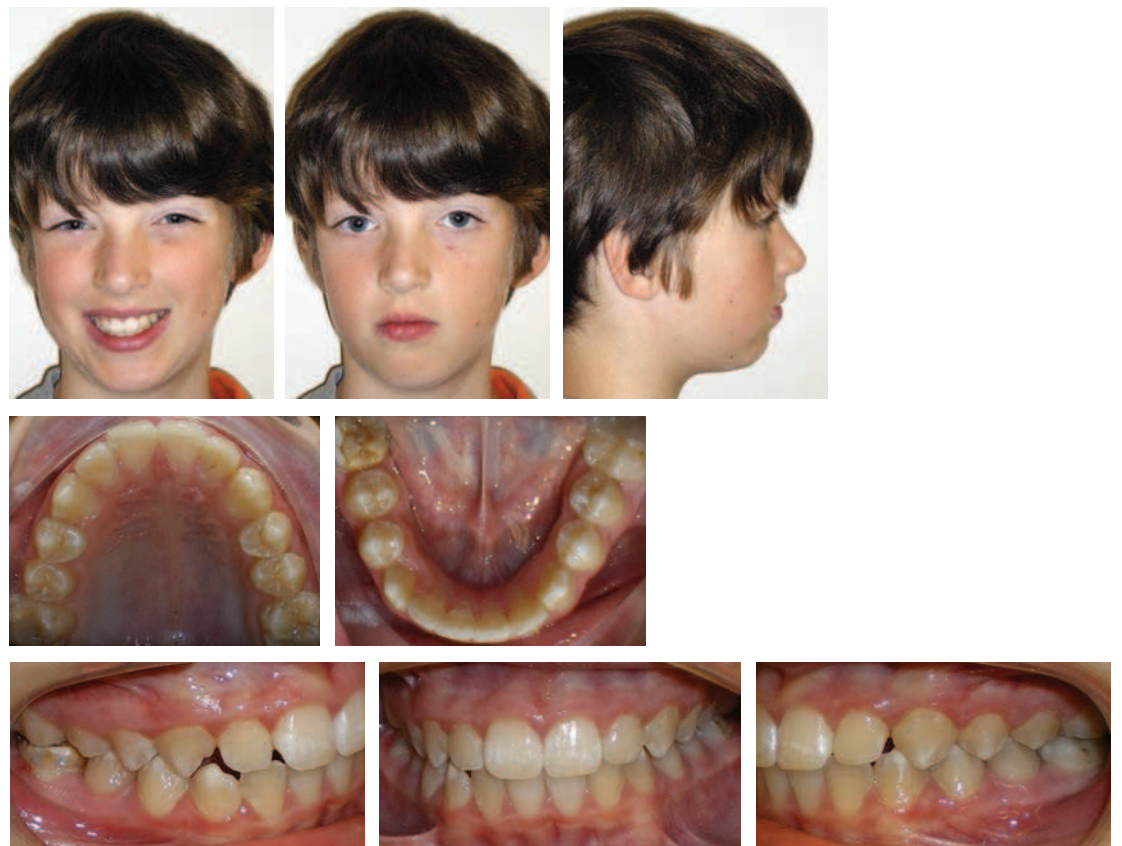
PRETREATMENT



POSTTREATMENT



**CHILD ALVEOLAR MODELING:
After Eruption of Permanent Teeth. Phase II Treatment was Not Pursued in this Case**



◀Page E4

**CASE STUDY 2
PERIADOLESCENT ALVEOLAR
MODELING:
Pretreatment**

Diagnosis

An 11.5-year-old female patient presented with a Class I jaw relationship and severe tooth size/arch length discrepancies with 9 mm of crowding in the maxillary arch and 15 mm of crowding in the mandibular arch. Her mandibular incisors were upright at 89° to the mandibular plane and she exhibited normal circumoral muscle tonus and competent lips. Her parents wanted to attempt a nonextraction treatment plan. Informed consent was obtained and a therapeutic diagnosis was initiated with a reassessment planned for approximately 6 to 9 months to determine if the nonextraction attempt could continue or if extraction would be required.

Treatment Summary

Damon protocols were employed with initial .013" Copper Ni-Ti wires and NiTi open-coil springs activated one-half-of-a-bracket width to begin to create space for the unbracketed, blocked-out teeth. Eyelet attachments were placed on the lingually blocked-out teeth and lightly ligated to the coil springs with enough force

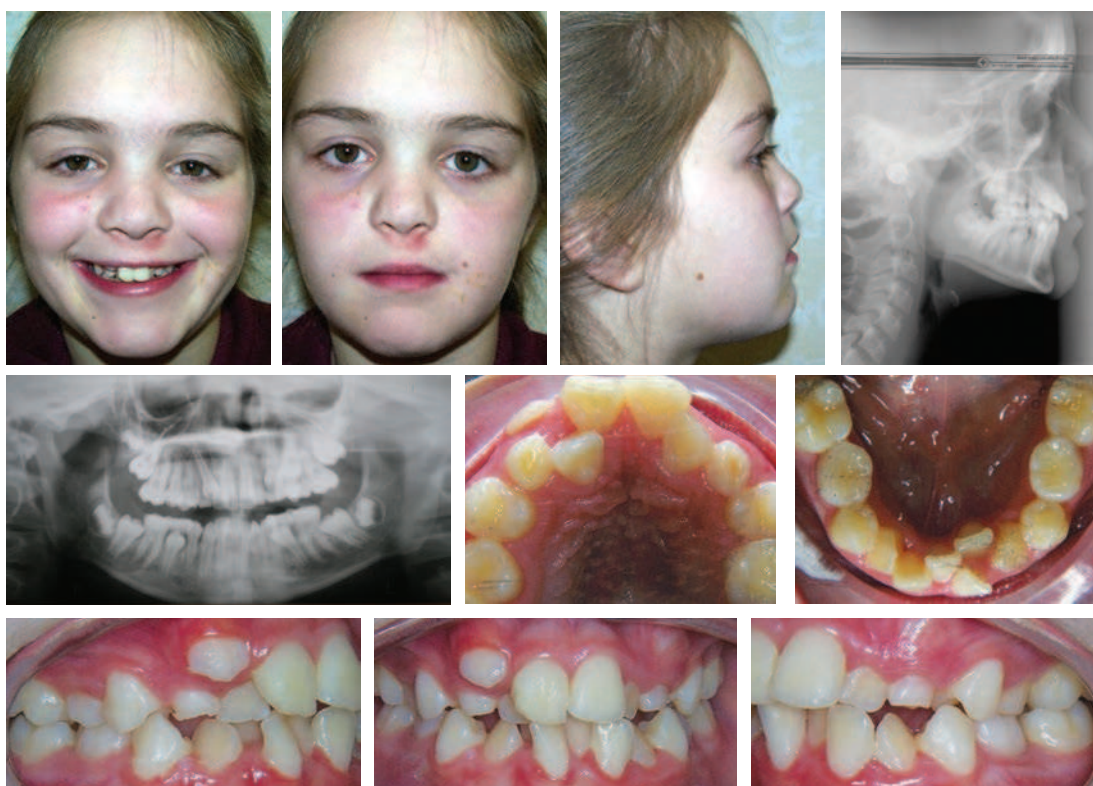to minimally deflect the archwire. Since the alignment at the 10-week appointment was deemed insufficient to engage a larger wire and comfortably close the bracket door, the initial wires were inspected for deformation and replaced. The springs were then reactivated and the blocked teeth religated and the patient reappointed for 8 weeks.

Although in significantly crowded cases the transitional wire is typically a .018" Copper

Ni-Ti wire engaged in preparation for a .014" x .025" Copper Ni-Ti wire, at the 18th week bracket alignment was again deemed insufficient for rectangular wire engagement so a .014" Copper Ni-Ti wire was placed, the springs were reactivated and the blocked-out teeth religated. At subsequent appointments as space was created, initially blocked-out teeth were bracketed and engaged with .014" Copper Ni-Ti wires. At 8.5 months, the decision was made to continue with the nonextraction treatment plan. This severely crowded case did not progress beyond the .018" Copper Ni-Ti wires until 12 months into treatment.

Results

The final result was obtained after



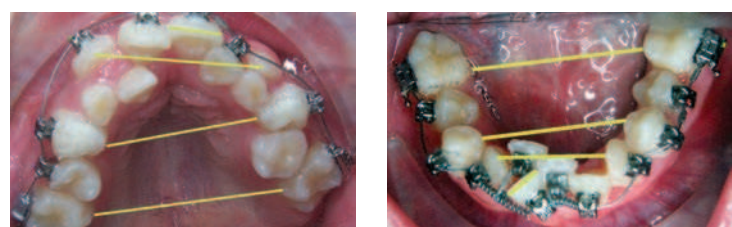
23 months of treatment. Retention included bonded lingual wire retainers and clear, vacuum-formed Essix-style removable retainers to be worn while sleeping. Sizecorrected lower occlusal photographs taken at initial

bonding and debonding illustrate the change in the size and shape of the mandibular alveolus induced by passive self-ligation treatment. By the three-year posttreatment follow up appointment, teeth #8 and #9

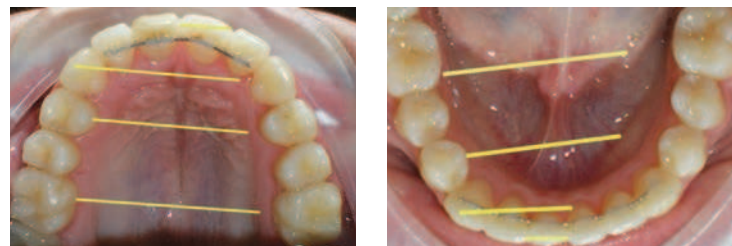had been crowned and the bonded maxillary lingual wire had been removed. The patient reported infrequent removable retainer wear and the alveolar modeling obtained had remained remarkably stable.

**PERIADOLESCENT ALVEOLAR MODELING:
Pre-/Posttreatment Comparison Demonstrates Alveolar Modeling**

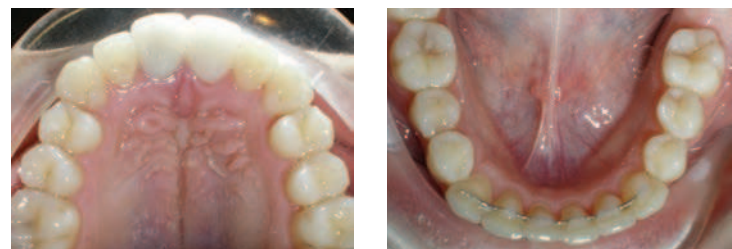PRETREATMENT



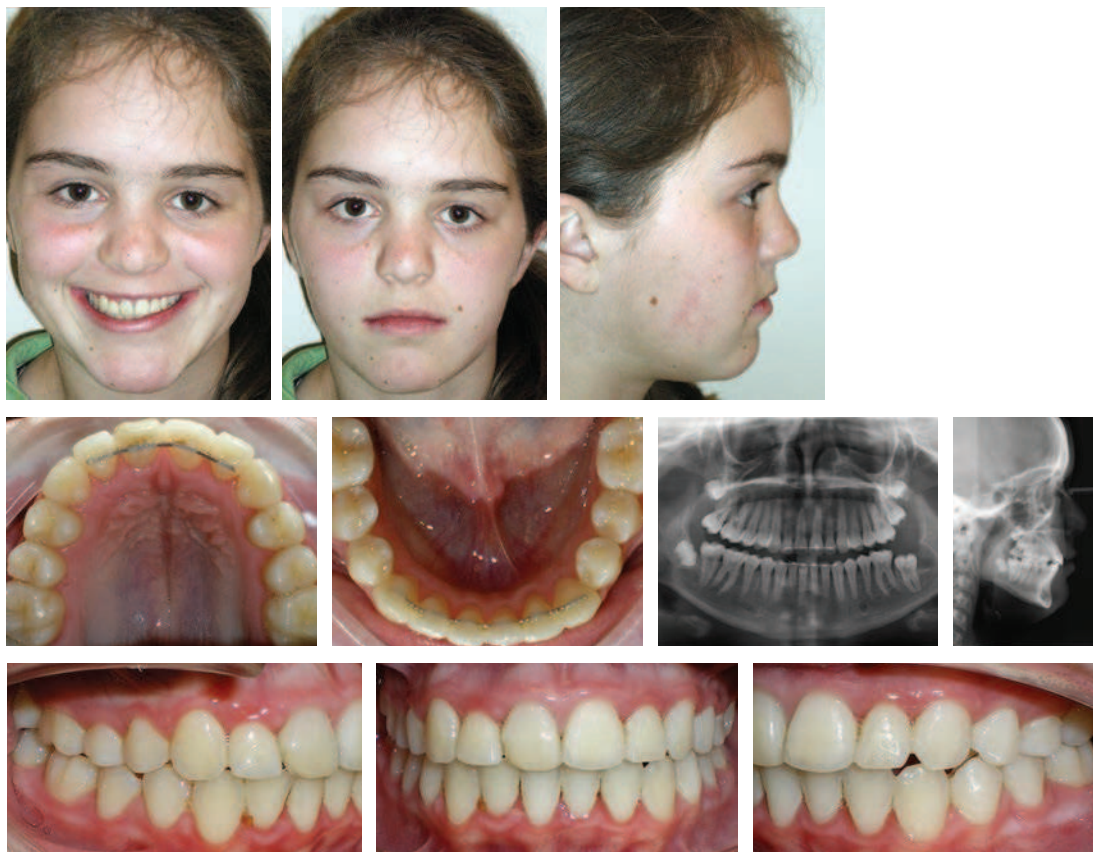POSTTREATMENT



3 YEARS POSTTREATMENT



**PERIADOLESCENT ALVEOLAR MODELING:
Results**



**CASE STUDY 3
ADOLESCENT ALVEOLAR MODELING**

Diagnosis

A female patient age 13 years, 5 months presented with a Class I malocclusion, crowding and constricted dental arches. Her case illustrates how muscular imbalance can have a constricting impact on the development of denoalveolar bone. The collapsed buccal segments and retroclined mandibular incisors are indicative of the influence of hypertonic buccinator and orbicularis oris muscles.

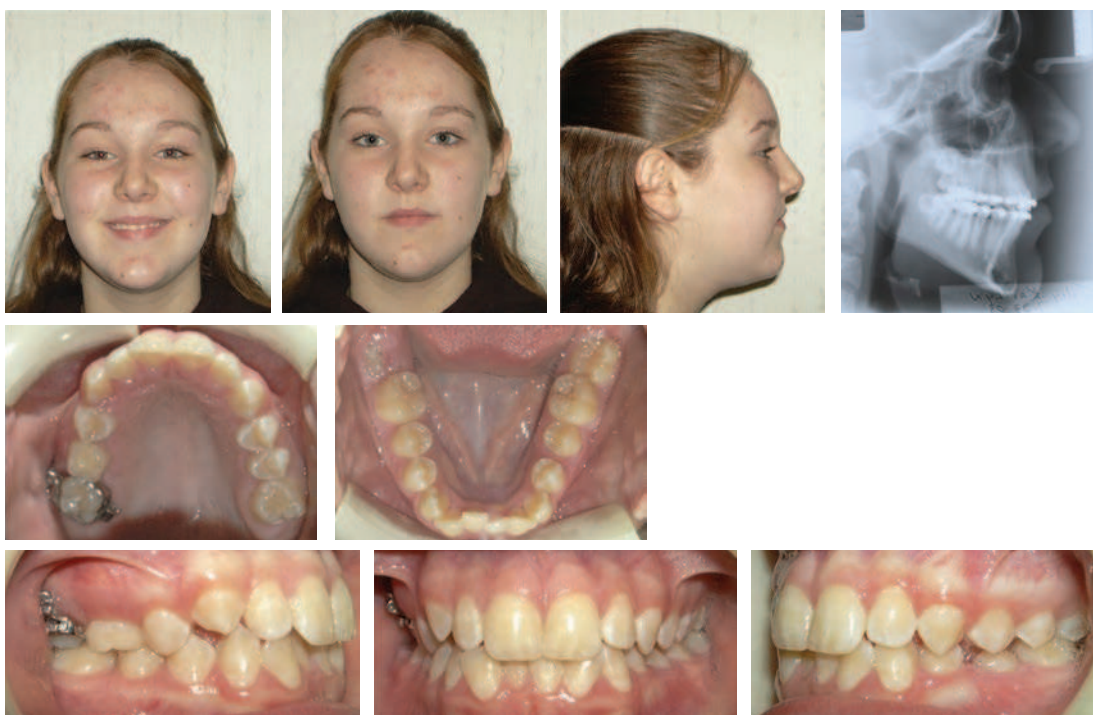Treatment Summary

The key element in cases like this are the leveling sequence and the use of turbos for disarticulation. It is essential to stay in round wires at least 6 months to give the muscles adequate time to rebalance; that is, to change the balance of forces between the overpowered tongue

muscle versus the muscles of the lips and cheeks. With passive self-ligation, muscles become an ally in treatment similar to the way the Frankel assists transverse development. The wire sequence in this case (both arches) was .013", .016" and .018" (6.5 months) Copper Ni-Ti followed by .014" x .025" and .018" x .025" Copper Ni-Ti (8 weeks each). The case was finished in .019" x .025" TMA (upper) and .017" x .025" TMA (lower).

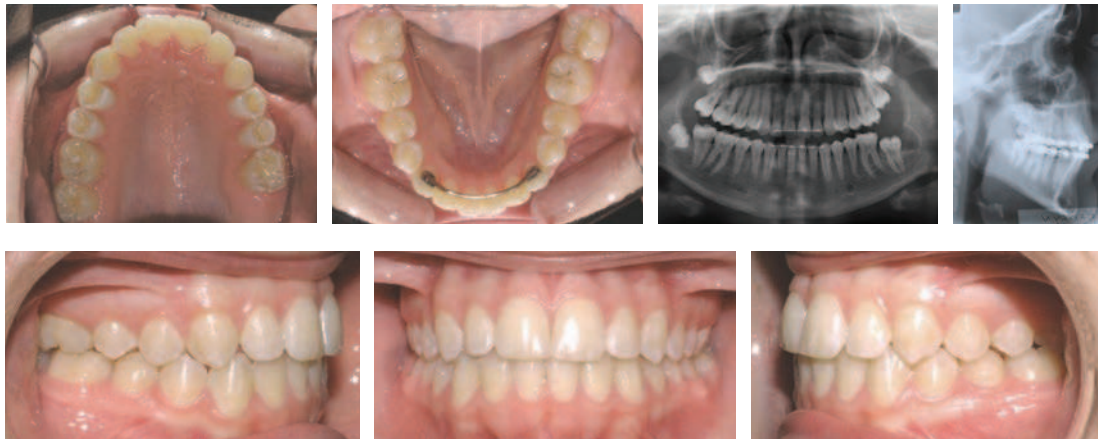Results

The case result was obtained in 19 months. The light, biomechanical load transmitted to the alveolar bone with a fixed, PSL appliance combined with small diameter, low-modulus-of-elasticity archwires demonstrates alveolar bone modeling as the teeth uprighted in the transverse dimension similar of the patient's mandibular arch.

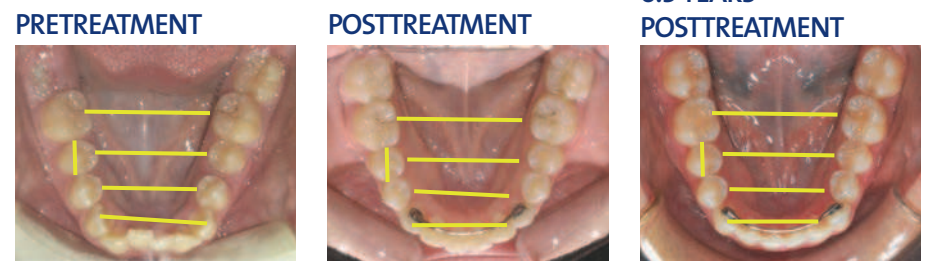


▶Page E6

**PERIADOLESCENT ALVEOLAR MODELING:
Results**

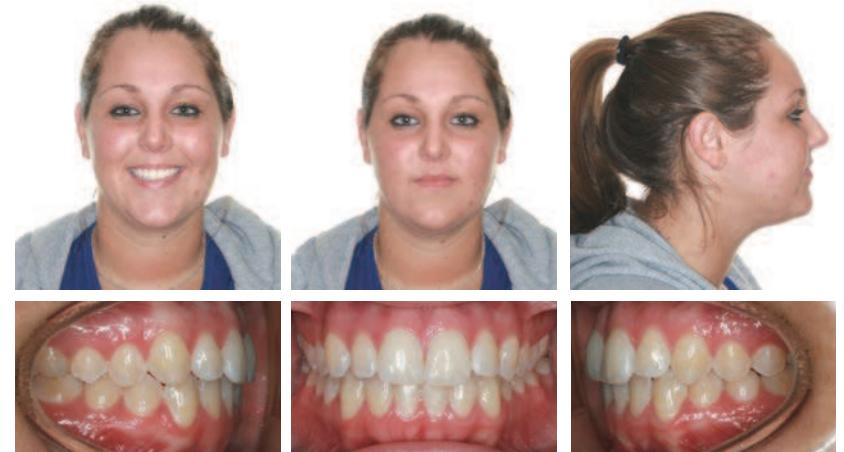

**ADOLESCENT ALVEOLAR MODELING:
Pre-/Posttreatment Comparison Demonstrates Esthetic Benefit
of Transverse Alveolar Bone Modeling**



Note: The mandibular canines in the patient's retention records seem to indicate significant expansion but is explained by the uprighting of these teeth over their apices.

**ADOLESCENT ALVEOLAR MODELING:
Stable Results 6.5 Years Posttreatment**



**CASE STUDY 4
ADULT ALVEOLAR MODELING:
Pretreatment**

Diagnosis

A 21-year-old female patient presented with an anterior open bite and bilateral, posterior cross bites. Her dental history included Phase I expansion and Phase II comprehensive treatment with another orthodontist. She was referred by an oral surgeon for orthognathic surgery to correct the open bite and constricted maxilla.

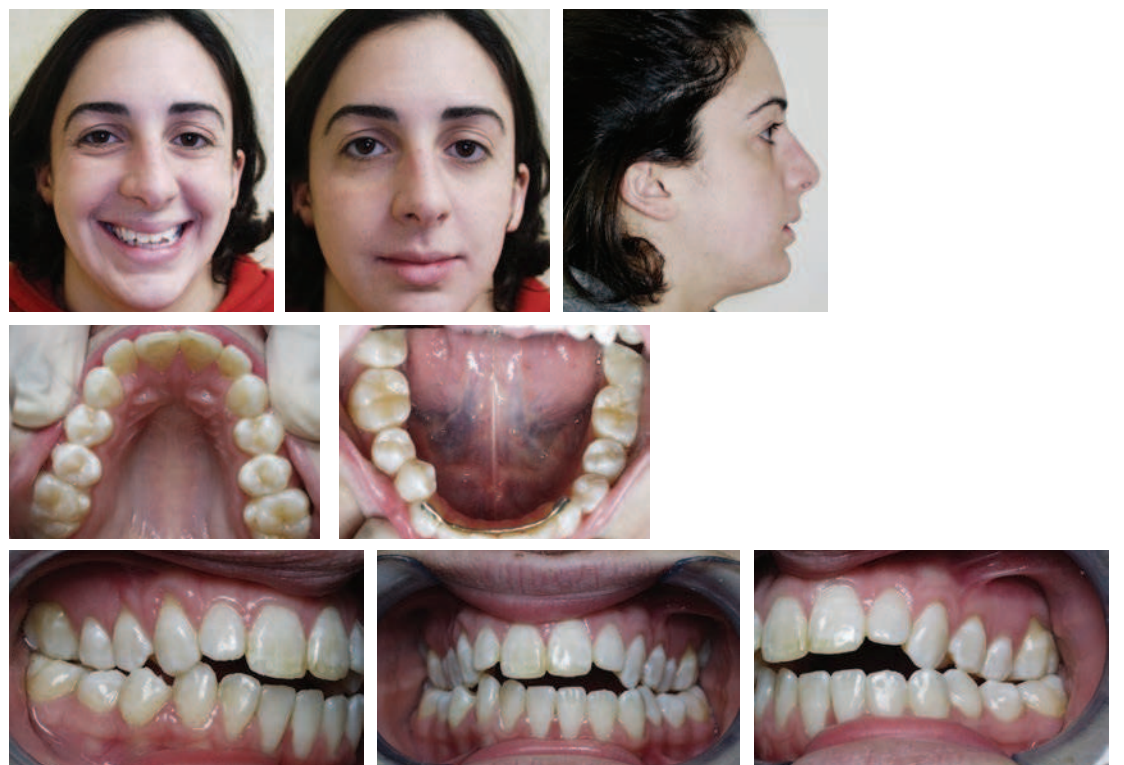Treatment Summary

Treatment was initiated using PSL appliances and lowfriction/low-force protocols with 2 oz. posterior cross elastics engaged bilaterally from attachments on the lingual surfaces of the maxillary second premolars and first molars to buccal attachments on the mandibular second premolars and first molars. The occlusion

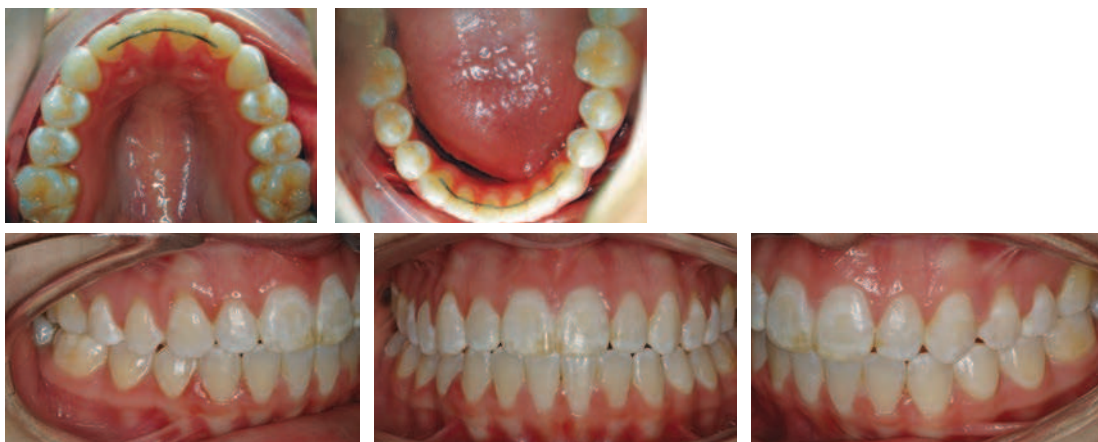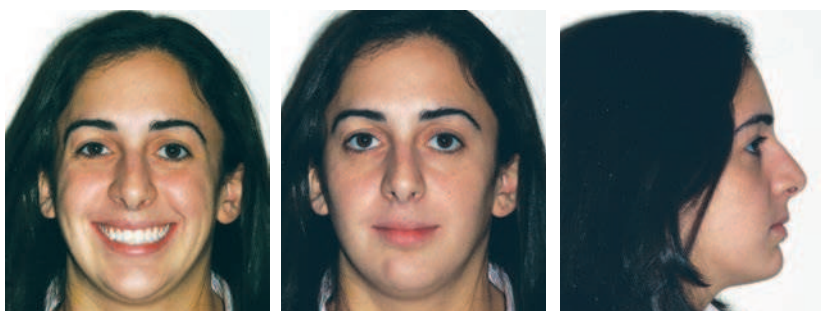
was disarticulated with flat-plane composite build-ups on the occlusal surfaces of the maxillary first and second molars. When the case progressed to the .019" x .025" stainless steel wires, the maxillary arch was sectioned bilaterally between the lateral incisors and canines in preparation for surgery. The surgeon, however, deemed that orthognathic surgery was no longer required. The case was finished with vertical elastics and retained with bonded lingual retainers and a Damon Splint retainer prescribed for nightly wear for the initial 12 months of retention.

Results

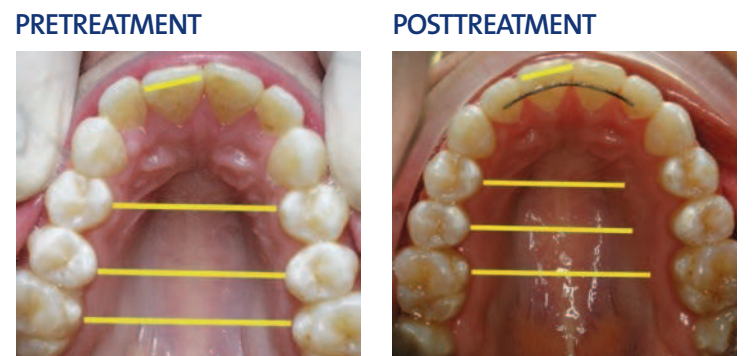
Treatment was completed in 21 months. Size-corrected upper occlusal photographs taken at bonding and debonding illustrate the change in the size and shape of the maxillary alveolus induced by passive self-ligation treatment. Unfortunately, the patient relocated and was unavailable for long-term follow up.



**PERIADOLESCENT ALVEOLAR MODELING:
Results**



**ADULT ALVEOLAR MODELING:
Pre-/Posttreatment Comparison Demonstrates Alveolar Modeling.
Surgery was Precluded in this Case.**



◀Page E6

Discussion

The case reports presented demonstrate examples of the change in the size and shape of the maxillary and mandibular alveolar bone observed in adolescent, adult and children treated with a passive self-ligating, continuous arch appliance and Damon low-friction/low-force treatment protocols. Specifically, the increase in the transverse dimension of the alveolus appears to be the result of lateral translation of the buccal and lingual cortical plates induced by the biomechanical load applied to the teeth and transmitted to the alveolar bone. These cases provide additional clinical evidence for the ability of the alveolar bone to undergo biomechanical load-induced modeling.

As Frankel had done previously with his Function Regulator appliance, Damon has proposed a mechanism of action for the dentoalveolar response to his treatment regimen. Based on clinical observations and analysis of photographs, plaster study model measurements and medical CT surveys³⁶ of treated cases, he suggests that the light, continuous force delivered by his treatment approach disrupts the equilibrium of the tooth positions maintained by the inner and outer oral musculature acting on the alveolus and dentition. When the anterior component of the force acting along the continuous archwire is kept low, it is mitigated by the resting pressure of the lip³⁸ in patients with adequate circumoral muscle tonus. The posterior component of force is likewise resisted by multi-rooted molars along with the ascending ramus in the mandible and the tuberosity in the maxilla. A resultant lateral component of force is expressed and transmitted from the teeth to the alveolar bone, inducing bone modeling or posterior arch adaptation as he describes it.

The OSIM findings of Badawi support Damon's proposed mechanism of action, specifically the assertion of a lower anterior vector of force delivered with a passive self-ligating appliance compared with an elastomeric-ligated appliance applied to the same simulated malocclusion. In addition, there is a cellular mechanism of action that supports alveolar bone modeling induced by tooth displacement. Figure 8 from Graber describes bone modeling occurring in the periodontal ligament and on the periosteal surfaces resulting from net apposition of bone in the direction of the line of applied force and net resorption of bone away from the direction of force. Furthermore, this ability to move bone with a light, continuous load applied to the teeth has been corroborated in the sagittal dimension by Melsen^{39,40} and Allais.⁴¹

Despite the evidence presented in this article, there remains considerable debate regarding the immutability of the alveolar bone and the treatment response to low-friction/low-force passive self-ligating appliances. Rigorous investigation should be undertaken to validate and understand these clinical observations. Future clinical investigations should incorporate case selection criteria that include subjects with adequate circumoral muscle tonus as well as close adherence to the established treatment protocols as described in the case reports above.

In addition, future CBCT analysis should consider the voxel size and resolution of the machines used in making alveolar bone determinations as well as the time period in which the posttreatment assessments are undertaken to allow adequate time for completion of sec-

ondary mineralization.

Conclusions

This article presents case reports demonstrating a change in the size and shape of the alveolar bone in child, adolescent and adult patients treated by a continuous-arch, self-ligating appliance. These cases, along with a growing body of evidence, challenge the immutability of the alveolar bone and the axiom of treating to the existing arch form. It is the authors' considered opinion that Melvin Moss's Functional Matrix Theory is correct and the change in alveolar form induced by this low-friction, low-force treatment approach provides an opportunity to recapture the full genetic potential of the patient's alveolus.

Furthermore, alveolar bone mode-

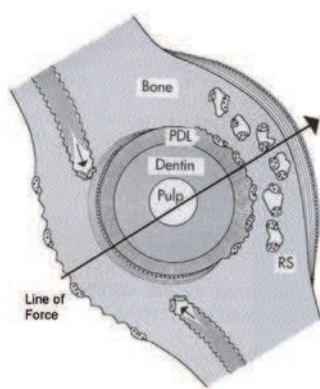


Figure 8. Orthodontic bone modeling, or sitespecific formation and resorption, occurs along the periodontal ligament and periosteal surfaces.

Illustration from *Orthodontics: Current Principles and Techniques*, Graber, Varnarsdall & Vig, 4th edition. Reprinted by permission.

ling is a practical treatment objective that can decrease the need for more invasive approaches in appropriately selected and appropriately treated patients.

Acknowledgment

The authors wish to acknowledge Dr. Rob Laraway, resident at the University of Maryland, Department of Orthodontics, for his assistance with the literature review for this article. [DTI](#)

Editorial notes:

References are available from the publisher.

Featured Article from *Clinical Impressions Journal*, Volume 20, Number 01, April 2017. Visit ormco.com/ci for more information



Thomas W. Barron, D.M.D., M.S.
Timonium, MD, USA
In the private practice of orthodontics, Dr. Barron is also a member of the Dean's

Faculty and an assistant clinical professor in the Department of Orthodontics at the University of Maryland School of Dental Medicine. He is a member of the Ormco speakers' bureau.



Frank Bogdan, D.M.D.
Bayonne, NJ, USA

In the private practice of orthodontics with his son Dr. Mark Bogdan, Dr. Bogdan is also an assistant clinical professor in the Department of Orthodontics at Rutgers University. He is also a member of the Ormco speaker's bureau.

International Magazines

ortho international magazine of orthodontics

www.dental-tribune.com



EUR 22 per year (2 issues per year; incl. shipping and VAT for customers in Germany) and EUR 23 per year (2 issues per year; incl. shipping for customers outside Germany).

Your subscription will be renewed automatically every year until a written cancellation is sent to Dental Tribune International GmbH, Holbeinstr. 29, 04229 Leipzig, Germany, six weeks prior to the renewal date.

Shipping Address

Name

Address

Zip Code, City

Country

E-mail

Date, Signature

PayPal Credit Card

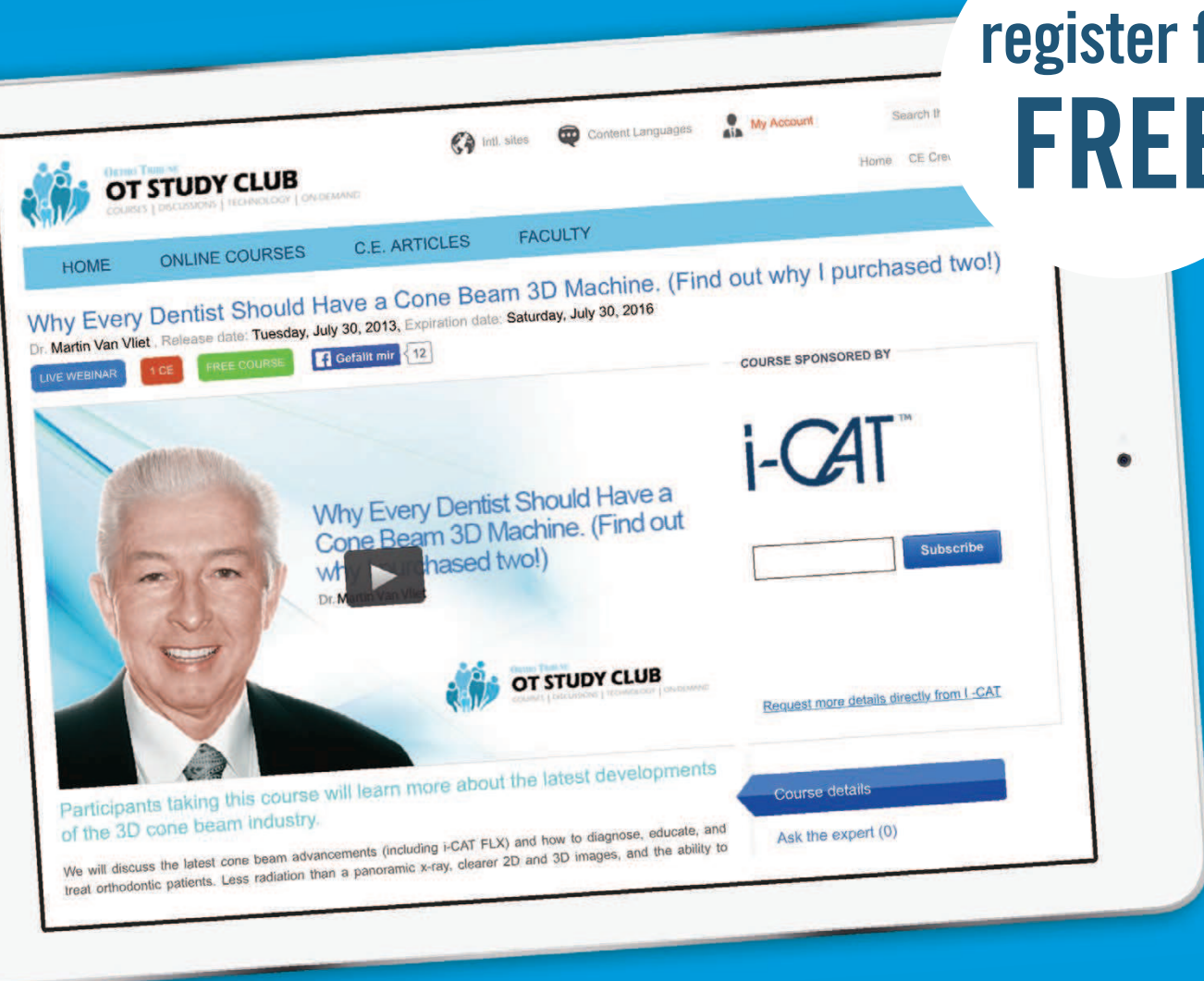Credit Card Number Expiration Date Security Code

SUBSCRIBE NOW!

F +49 341 48474 173
subscriptions@dental-tribune.com



register for
FREE



- education everywhere and anytime
- live and interactive webinars
- a focused discussion forum
- free membership
- no travel costs
- no time away from the practice
- interaction with colleagues and experts across the globe
- a growing database of scientific articles and case reports
- ADA CERP-recognized credit administration

www.OTStudyClub.com

Ortho Tribune Study Club

**Join the largest
educational network
in orthodontics!**

ADA CERP® | Continuing Education
Recognition Program

ADA CERP is a service of the American Dental Association to assist dental professionals in identifying quality providers of continuing dental education. ADA CERP does not approve or endorse individual courses or instructors, nor does it imply acceptance of credit hours by boards of dentistry.



ORTHO TRIBUNE
OT STUDY CLUB
COURSES | DISCUSSIONS | TECHNOLOGY | ON-DEMAND

dti | Dental
Tribune
International